NeuroImage 224 (2021) 117439

Contents lists available at ScienceDirect

NeuroImage

journal homepage: www.elsevier.com/locate/neuroimage

Review

Cortico-spinal imaging to study pain

Alexandra Tinnermann[a,b,*], Christian Büchel[a,b], Julien Cohen-Adad[c,d,*]

[a] Department for Systems Neuroscience, University Medical Center Hamburg-Eppendorf, Hamburg, Germany
[b] Max Planck School of Cognition, Leipzig, Germany
[c] NeuroPoly Lab, Institute of Biomedical Engineering, Polytechnique Montreal, Montreal, Quebec, Canada
[d] Functional Neuroimaging Unit, CRIUGM, Université de Montréal, Montreal, Quebec, Canada

ARTICLE INFO

Keywords:
fMRI
Spinal cord
Cortico-spinal imaging
Combined imaging
Pain
Pain processing

ABSTRACT

Functional magnetic resonance imaging of the brain has helped to reveal mechanisms of pain perception in health and disease. Recently, imaging approaches have been developed that allow recording neural activity simultaneously in the brain and in the spinal cord. These approaches offer the possibility to examine pain perception in the entire central pain system and in addition, to investigate cortico-spinal interactions during pain processing. Although cortico-spinal imaging is a promising technique, it bears challenges concerning data acquisition and data analysis strategies. In this review, we discuss studies that applied simultaneous imaging of the brain and spinal cord to explore central pain processing. Furthermore, we describe different MR-related acquisition techniques, summarize advantages and disadvantages of approaches that have been implemented so far and present software that has been specifically developed for the analysis of spinal fMRI data to address challenges of spinal data analysis.

1. Introduction

1.1. Overview

A common and non-invasive method to study the neurobiological mechanisms of pain processing in humans is functional imaging of the brain. However, pain processing comprises the entire central nervous system including the spinal cord. Therefore, more and more studies also apply functional imaging of the spinal cord to investigate pain processing. Furthermore, several approaches have been developed that allow the simultaneous measurement of neural responses in the brainstem and spinal cord (Stroman et al., 2008) and even in the whole brain and spinal cord (Cohen-Adad et al., 2010; Finsterbusch et al., 2013; Islam et al., 2019). The latter possibility is particularly interesting for pain research because it allows investigating the entire central pain system in humans non-invasively. One important advantage of simultaneous cortico-spinal imaging compared to imaging the brain and spinal cord separately is the option to study interactions between the spinal cord and the brain during pain processing. In this review, we will highlight studies in the field of pain research that applied simultaneous cortico-spinal imaging and related approaches to elucidate how cortico-spinal imaging can help to unravel new aspects of pain processing. Furthermore, we will highlight the existing acquisition techniques of cortico-spinal imaging with their advantages and disadvantages, and discuss data analysis strategies.

1.2. The human pain system

The human pain system consists of interconnected ascending and descending pathways (Fields, 2004) (Fig. 1). The ascending pathway conveys nociceptive information from the periphery (skin, viscera) to the spinal cord through specialized fibers. These nociceptors synapse in the ipsilateral dorsal horn of the spinal cord from where the ascending pathway continues predominantly via the spinothalamic tract. The spinothalamic tract crosses to the contralateral side of the spinal cord and then ascends to the thalamus. Subsequently, the ascending pathway diverges to different brain regions such as the somatosensory cortex, insula and cingulate cortex (Fields, 2004). It is thought that the ascending pathway conveys information about the intensity, quality and location of the pain (Apkarian et al., 2013). The spinal cord is divided into segments that innervate different skin areas or dermatomes (Lee et al., 2008). This somatotopic relationship between dermatomes and their corresponding spinal cord segments has been shown to be partially preserved in the somatosensory cortex and insula (Bingel et al., 2004; Brooks et al., 2005; Mancini et al., 2012; Mazzola et al., 2009).

In contrast to the ascending pain pathway, the descending pain pathway is considered a modulatory pathway that can modify nociceptive information at various levels of the central pain system (Fields, 2004; Heinricher et al., 2009). The descending pathway has been extensively studied in animals and comprises brainstem structures such as the peri-

* Corresponding authors at: Department for Systems Neuroscience, University Medical Center Hamburg-Eppendorf, Hamburg, Germany.
E-mail addresses: a.tinnermann@uke.de (A. Tinnermann), jcohen@polymtl.ca (J. Cohen-Adad).

https://doi.org/10.1016/j.neuroimage.2020.117439
Received 8 May 2020; Received in revised form 21 September 2020; Accepted 1 October 2020
Available online 8 October 2020
1053-8119/© 2020 The Authors. Published by Elsevier Inc. This is an open access article under the CC BY-NC-ND license
(http://creativecommons.org/licenses/by-nc-nd/4.0/)

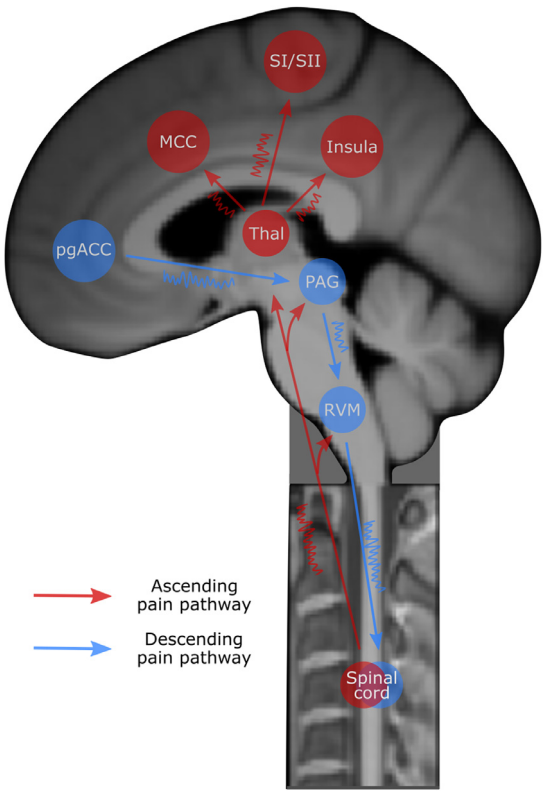

Fig. 1. Schematic overview of the ascending (red) and descending (blue) pain pathways overlaid on a combined anatomical template of the brain (T1 MNI152 template) and spinal cord (PAM50 template). pgACC: pregenual anterior cingulate cortex; MCC: middle cingulate cortex; Thal: thalamus; SI/SII: primary and secondary somatosensory cortex; PAG: periaqueductal gray; RVM: rostral ventromedial medulla.

aqueductal gray (PAG) and the rostral ventromedial medulla (RVM). The PAG has been found to exert a top-down control via the RVM onto the spinal cord through inhibition and facilitation of the incoming peripheral nociceptive information (Melzack and Wall, 1965) and can thus regulate the amount of nociceptive information that is conveyed to the brain via the ascending pain pathway. Results from studies in humans (Bingel et al., 2006; Eippert et al., 2009a; Kong et al., 2010; Petrovic et al., 2002) and animals (Chen et al., 2018; Senapati et al., 2005) suggest that in addition to brainstem and spinal structures, the pregenual anterior cingulate cortex (pgACC), sometimes also referred to as rostral ACC, is a key cortical structure in pain modulation that exerts top-down influences on the PAG and spinal cord. As a result, the pgACC has been included in more recent definitions of the descending pain system (Apkarian et al., 2013; Bushnell et al., 2013; Geuter et al., 2017). For a more detailed description of the human pain system and specific contributions of individual brain regions in pain processing, the reader is referred to (Apkarian et al., 2013; Dostrovsky and Craig, 2013; Heinricher and Fields, 2013).

Based on the anatomy of ascending and descending pathways, the central pain system is a distributed network that comprises cortical, subcortical and spinal regions. Investigating this system as a whole in humans can help to shed light on important aspects of pain processing in health and disease.

1.3. Representation of pain in the central nervous system

The question where pain is processed in the brain has interested researchers for decades (Melzack and Casey, 1968; Penfield and Boldrey, 1937). However, only with the advent of neuroimaging techniques did it become possible to show that pain is processed within a distributed network across the brain. Imaging studies consistently showed that brain regions activated by noxious stimulation comprise the thalamus, primary and secondary somatosensory cortex, insula and middle cingulate cortex (MCC, which is often referred to as dorsal anterior cingulate cortex (dACC) (Heilbronner and Hayden, 2016)), among other regions (Apkarian et al., 2005; Duerden and Albanese, 2013). This activation pattern resulted in the concept of the 'pain neuromatrix' (later 'pain matrix'), a pain processing related network, that was divided into a sensory-discriminative and a cognitive-affective component (Melzack, 1999). Although stimulation of the secondary somatosensory and posterior insula has been shown to elicit noxious sensations in awake humans (Mazzola et al., 2006), none of the brain regions involved in pain processing has been shown to be pain-specific (Davis et al., 2015; Wager et al., 2016). Therefore, the co-activation of regions within the 'pain matrix' has been considered as being pain-specific but this concept has been challenged and criticized alike in the scientific literature (Iannetti and Mouraux, 2010; Legrain et al., 2011; Liang et al., 2011; Mouraux et al., 2011; Salomons et al., 2016). Nonetheless, activation within this pain-related network including regions such as secondary somatosensory cortex, insula and MCC (dACC) has been shown to be related to individual pain perception in healthy participants (Brodersen et al., 2012; Favilla et al., 2014; Lindquist et al., 2017; Wager et al., 2013). Moreover, approaches that combined activity from common pain-processing brain regions performed better in explaining pain ratings compared to considering activity in single brain regions (Brodersen et al., 2012). In line with this observation, the Neurological Pain Signature that weighs voxels based on their contribution to predict pain perception identified high predictive weights in sensory regions and the MCC (dACC) (Wager et al., 2013).

Although technically challenging, the next step was to apply functional neuroimaging to spinal cord structures. Animal studies have shown that spinal BOLD activity reflects electrical activity (Piché et al., 2017) and that hemodynamic responses to noxious stimulation show similar time courses in the somatosensory cortex and the spinal cord (Yang et al., 2015). Nevertheless, spinal imaging is more susceptible to distortions and signal loss mainly due to cerebrospinal fluid fluctuations and magnetic field inhomogeneities in the neck (Bosma and Stroman, 2014; Brooks et al., 2012; Eippert et al., 2017a; Kong et al., 2012; Piché et al., 2009). Because of these challenges, one goal in spinal fMRI was to investigate the plausibility of spinal activity based on the anatomy of the ascending pain pathway. In line with the anatomical location of peripheral nerve endings, several studies reported pain-related spinal activation in the dorsal horn ipsilateral to the stimulation site (Bosma and Stroman, 2015; Brooks et al., 2012; Eippert et al., 2009b; Nash et al., 2013; Sprenger et al., 2018, 2012). Furthermore, noxious stimulation within dermatomes of different body parts elicited activity in corresponding spinal segments, i.e. followed a somatotopic organization (Nash et al., 2013; Stroman et al., 2012). A spinal fMRI study in monkeys further demonstrated through tracer histology that the spinal segment showing stimulation-related BOLD responses received afferent nerve input from the stimulated skin area (Yang et al., 2015). After spinal fMRI was successfully developed, researchers began to develop techniques that allow simultaneous recording of BOLD responses in both brain and spinal cord, as this allows to investigate pain processing along the entire central nervous system.

2. Application of cortico-spinal imaging in pain research

2.1. Nonsimultaneous cortico-spinal imaging

Due to technical limitations, first studies that investigated cortico-spinal responses to noxious stimulation recorded neural activity separately in the brain and spinal cord in either successive sessions, or in two groups of participants. One study that implemented this approach recorded neural responses in the brain and spinal cord to investigate how listening to one's favorite music modulates pain perception and

pain processing in comparison to not listening to music (Dobek et al., 2014). In this study BOLD responses in the brain and spinal cord were recorded separately in two successive sessions. In a similar experimental setup, participants received a series of short, oscillating heat stimuli and brain and spinal regions were identified that correlated with perceived pain intensity (Khan and Stroman, 2015). Another study investigated opioid-induced hyperalgesia separately within the brain and spinal cord in two groups of participants (Sprenger et al., 2018). Importantly, both groups underwent the same experimental procedure. Results show that pain sensitivity as well as BOLD responses in the insula, thalamus, amygdala and RVM were increased after remifentanil treatment. This indicates that opioid-induced hyperalgesia, which manifests upon opioid withdrawal (Angst et al., 2003) is represented in pain-related brain regions. At the spinal level, activity within the dorsal horn was able to dissociate whether participants received saline or remifentanil, indicating that opioids modulate spinal nociceptive processing after drug cessation.

2.2. Brainstem-spinal imaging

The first approach that measured neural responses simultaneously in the brain and spinal cord, extended the field of view from the spinal cord to the brainstem. Studies using this approach have shown that mechanical and thermal pain increase activity in the spinal cord dorsal horn and brainstem regions such as the PAG or RVM (Cahill and Stroman, 2011; Ghazni et al., 2010). Furthermore, physiological modulation of pain responses such as temporal summation, sensitization or secondary hyperalgesia were associated with increased activity in the spinal cord and altered processing within the descending pain pathway (Bosma et al., 2015; Rempe et al., 2015, 2014). Similar to spinal fMRI studies, brainstem-spinal fMRI studies have shown that emotion- and attention-related pain modulation do not only affect neural responses in the spinal cord but also in the brainstem (McIver et al., 2018; Stroman et al., 2011). Other studies have investigated connectivity between the brainstem and spinal cord in different conditions in relation to noxious stimulation (Stroman et al., 2016a, 2018) and how this connectivity is altered in patients with spinal cord injury (Stroman et al., 2016b).

2.3. Proof-of-concept cortico-spinal imaging in pain perception

Subsequently an approach was presented that allowed fMRI in the brain and spinal cord using different fields of view, slice orientation and in-plane resolution (Finsterbusch et al., 2013). The first study to use this approach investigated BOLD activity in the brain and spinal cord in response to two different heat pain intensities (Sprenger et al., 2015). The low intensity (46°C) was mildly painful while the high intensity (47°C) was moderately painful. Heat pain stimuli were applied on the left radial forearm that corresponds to dermatome C6 (Lee et al., 2008). Brain regions such as the thalamus, primary and secondary somatosensory cortices, insula and dorsal ACC showed increasing activity levels in response to increasing intensities. In addition, the left dorsal horn of the spinal cord within spinal segment C6 showed similar responses with respect to the two pain intensities, which corroborates findings from a study that compared spinal activation patterns to painful and innocuous stimuli (Summers et al., 2010). The location of the spinal cluster was further compared to peak voxel activity in two other pain related spinal fMRI studies (Eippert et al., 2009b; Sprenger et al., 2012). The overlay shows that the peaks of pain-related activation were located at the upper part of the fifth vertebra. In line with this finding, anatomical studies in humans have shown that spinal segment C6, which receives input from peripheral nerves within dermatome C6, corresponds mostly to the spinal cord segment within the upper part of the fifth cervical vertebrae (Cadotte et al., 2015; Kim et al., 2012).

In a next step, the authors investigated functional connectivity between the brain and the spinal cord and extracted the time course of the BOLD response at the peak voxel in the spinal cord and correlated that time course with time courses in the brain. Neural coupling between the dorsal horn activity and brain regions such as the thalamus, primary somatosensory cortex, insula, striatum, amygdala, hypothalamus and midbrain was observed. In addition, the coupling strength between the spinal cord and the PAG correlated with behavioral pain ratings suggesting that increased pain levels are associated with increased coupling between the spinal cord and the brainstem. This result expands on findings from previous studies that investigated pain-related connectivity in the brain (Ploner et al., 2010; Zaki et al., 2007). The results of this first cortico-spinal fMRI study show that besides its feasibility to detect pain-related activation patterns in the brain and spinal cord, it can add novel insights concerning functional connectivity between the spinal cord and different brain and brainstem regions.

2.4. Investigating descending modulation with cortico-spinal imaging

The second cortico-spinal imaging study in the field of pain investigated the influence of expectation-induced pain modulation on the interaction between the spinal cord and the brain (Tinnermann et al., 2017). In this study, nocebo hyperalgesia was induced in two groups of participants using a (supposedly) pain-intensifying cream. In addition, the value of the cream was manipulated between the two groups to investigate whether cognitive factors such as value further modulate nocebo hyperalgesia. The value of a medication (e.g. price information) has been previously shown to modulate placebo analgesia: branding of an inert painkiller lead to stronger placebo effects than administering a non-branded or generic painkiller (Branthwaite and Cooper, 1981; Fehse et al., 2015). Moreover, providing explicit price information was accompanied by weaker placebo effects if participants received a price-reduced compared to a regular-priced drug (Waber, 2008). Based on these studies, the question arose whether a medication's value not only influences the perceived effectiveness but also the perceived harm (e.g. side effects) that medical treatments can cause. To implement the value aspect in a nocebo paradigm, participants were randomly assigned to test either a cheap or expensive version of the cream. The cover story for this pain-intensifying medical cream made participants believe that it was used in atopic dermatitis patients to treat itch and that one common side effect was increased heat sensitivity. Importantly and unknown to the participants, both creams did not contain any active agent. Instead, to let participants experience the supposedly side-effect induced pain increase, temperatures on the cream-treated skin were surreptitiously increased compared to a control skin patch. After this experience-induction, participants were scanned using cortico-spinal imaging while temperatures were identical on the control and cream-treated skin patches. Pain ratings showed that participants who received the expensive cream reported increased pain levels compared to those who received the cheap cream indicating that expensive medication can enhance expectancies about possible side effects. To ascertain the validity of the cortico-spinal imaging approach, neural responses during noxious stimulation irrespective of nocebo expectations and value were analyzed and similar pain-related activity in the brain and spinal cord was detected as in the previous cortico-spinal fMRI study by Sprenger and colleagues (2018) (Fig. 2). Nocebo-related activity was observed in the spinal cord at the height of spinal segment C6 similar to the results of a previous nocebo-related spinal fMRI study (Geuter and Büchel, 2013). Within the brain, two regions of the descending pain pathway showed both nocebo- and value-related activity: activity in the pgACC correlated negatively with the magnitude of behavioral nocebo effects irrespective of value, and the PAG showed increased activity in the expensive nocebo group compared to the cheap group, therefore reflecting the value-related modulation of nocebo hyperalgesia. These findings are in line with previous studies that reported placebo-related activity in the PAG and/or pgACC (Eippert et al., 2009a; Peciña et al., 2012; Petrovic et al., 2002; Scott et al., 2008; Wager et al., 2007). Similarly, expectancies about placebo treatments have been shown to be encoded in the pgACC (Geuter et al., 2013; Kong et al., 2009). Based on these findings, time

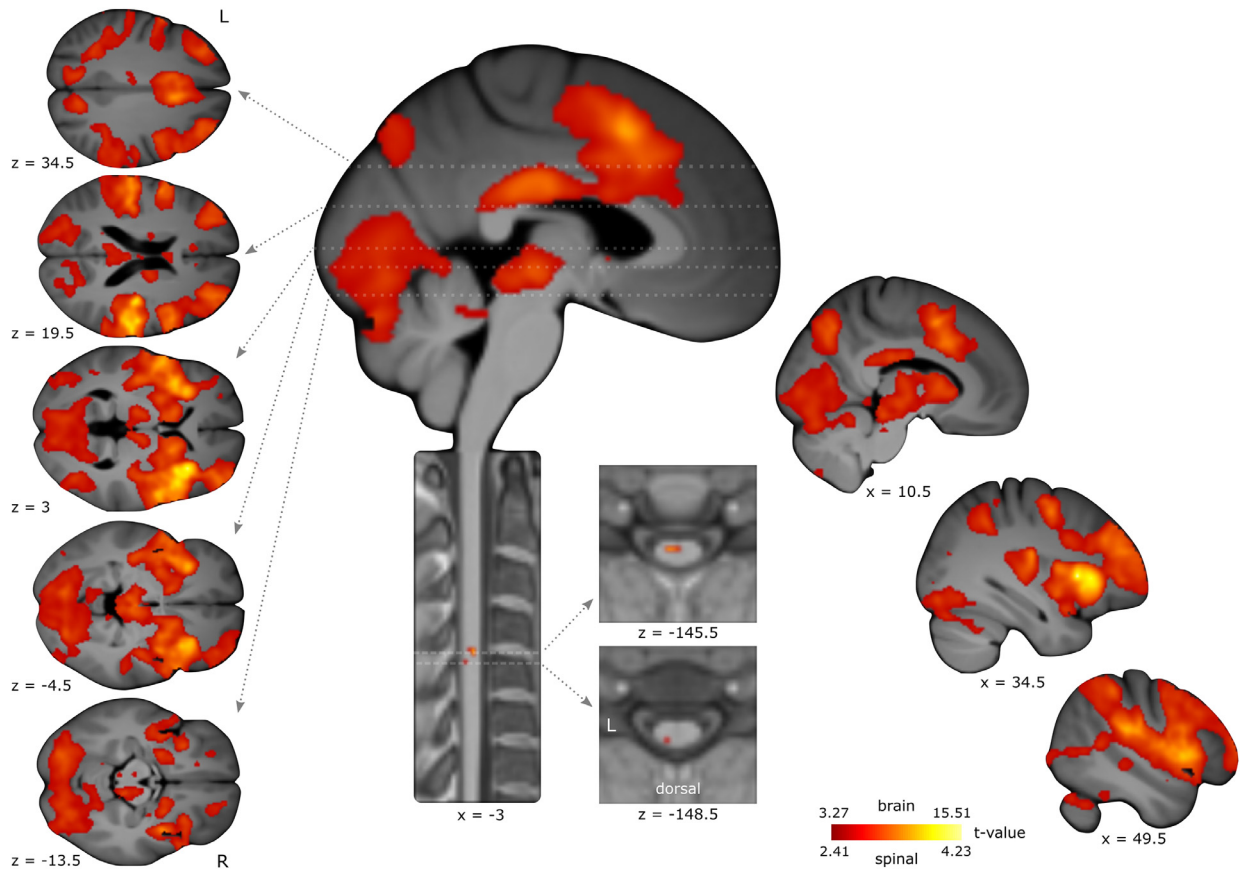

Fig. 2. Main effect of pain in the brain and spinal cord from a cortico-spinal imaging study (Tinnermann et al., 2017) in 49 participants overlaid on a combined anatomical template of the brain (T1 MNI152 template) and spinal cord (PAM50 template). Noxious heat was applied on the left volar forearm on dermatome C6. The ipsilateral spinal cord at the height of segment C6 showed pain-related activation in the dorsal horn and motor-related activation in the ventral horn. Similarly, pain related regions in the brain such as the brainstem, thalamus, somatosensory cortex, insula and MCC (dACC) displayed activity in response to noxious stimulation.

courses of the spinal and prefrontal clusters were extracted for connectivity analyses. Both regions showed coupling with the PAG that correlated with the magnitude of individual nocebo effects. The value of the medical cream further influenced the coupling between pgACC and PAG and between spinal cord and PAG in opposite directions suggesting that the PAG might integrate signals from ascending and descending pain pathways. The results of this study show that expectation and value-induced pain modulation are represented along the descending pain pathway and that cortico-spinal imaging is an adequate technique to investigate modulatory changes in connectivity along the descending pain pathway.

3. Technical considerations

Spinal cord fMRI remains methodologically very challenging. Combined cortico-spinal fMRI poses even more methodological challenges. Reasons include a poor static signal-to-noise ratio (SNR) related to the poor physical coverage of the receive coil (Cohen-Adad and Wald, 2014), a poor temporal SNR related to high signal fluctuations from the non-desired baseline physiology (cardiac pulsation, breathing) (Piché et al., 2009) and susceptibility artifacts, which produce signal dropout and image distortion when using EPI readout (Saritas et al., 2014). Moreover, there exist differences in the neurovascular coupling and vasculature structure between the spinal cord and the brain, contributing to potential differences in sensitivity to the BOLD effect between those two structures (Cohen-Adad, 2017). Beyond challenges related to acquiring images covering the brain and spinal cord, there are additional difficulties related to the analysis of these data, because standard neuroimaging software was mainly developed to process brain data. In this section, we will first focus on fMRI acquisition strategies for the brain-spine axis, and then we will cover strategies related to data analysis. For additional reviews on this topic see (Cohen-Adad, 2017; David et al., 2019; Seif et al., 2019; Stroman et al., 2014; Summers et al., 2014).

3.1. Acquisition techniques

3.1.1. Field strength

The higher susceptibility effect at higher field strength is both a blessing and a curse. While sensitivity to the BOLD effect increases, there are also more challenges related to image acquisition. The biggest one being the increase in susceptibility artifacts, yielding image distortions when using fast readout (e.g., EPI) as traditionally done with fMRI protocols, as well as signal dropout caused by intravoxel dephasing. The latter effect is particularly prominent in axial spinal cord scans, where slice thickness is typically several mm thick in order to maximize SNR (Summers et al., 2014).

That being said, as will be described in the subsequent subsections, there are various ways to compensate for susceptibility artifacts and benefit from a higher magnetic field strength. The study by Barry and colleagues (2016) in which resting-state fMRI in the spinal cord at 7T was assessed is a good example of what is currently possible at 7T.

3.1.2. RF coils

Radiofrequency (RF) coils are key to providing sufficient image quality for brain-spine fMRI protocols. A 7T MRI with a sub-optimal coil can sometimes yield poorer results than a 3T MRI with a highly performant array coil. The rule of thumb when designing and using coils is that

RF transmission should be as homogeneous as possible (assessed by the so-called B1+ or flip angle mapping), while RF reception should be as sensitive as possible (image SNR is directly related to the reception). At 3T, RF transmission is typically done by the body coil (integrated in the MR system bore), which has excellent homogeneity. For RF reception, most manufacturers now provide array coils, which are composed of multiple loops (up to 32, 64 or 128 depending on the coil and number of receive channels of the MR system) laid out on the plastic cover of the coil as to image a specific region. For head-neck protocols, it is advisable to choose coils that cover this region as best as possible. A consensus head-neck acquisition multi-vendor protocol (Cohen-Adad, 2020) suggested the following coils:

- Siemens (Skyra/Prisma/Vida): 64ch head/neck (preferred) or 16+4ch.
- Siemens (Trio/Verio): 12ch brain + 4ch neck array. If thoracolumbar, use spine array.
- Philips: 16ch neurovascular
- GE: 16ch Head Neck Spine (HNS) Array (on MR750 systems). If not available, use 8ch Cervical Thoracic Lumbar (CTL) Array combined with a head coil.

For more details on RF coils the reader is referred to (Cohen-Adad and Wald, 2014).

3.1.3. Active shimming

Shimming consists in homogenizing the static magnetic field (B_0) while doing MRI experiments. This is a necessary step to record reliable images, especially in regions that are prone to large B_0 inhomogeneities such as the orbitofrontal cortex, lower brain, brainstem and spinal cord. In addition, without proper shimming, fat saturation would not work effectively, slice excitation profiles would not be accurate and EPI data could show distortions and signal drop out.

The very first "active" attempt to mitigate susceptibility artifacts is usually performed just before starting an fMRI scan via a procedure called active shimming. This procedure consists in estimating a field map and then computing a set of "shim coefficients" that describe the amount of current going into each gradient and shim coil necessary for minimizing the static magnetic field inhomogeneity in the specified region (typically, the field of view of the image to be acquired). Fig. 3A shows the effect of using single order (only gradients) versus 2nd order shimming (gradients + shim coils) for homogenizing the magnetic field during an acquisition.

However, the default shim coils that are integrated in the MR system are usually not sufficient to compensate for the high spatial variations of the magnetic field across the brain-spine axis, which motivated the development of custom high-order shim coils (Hetherington et al., 2006; Topfer et al., 2016). A recent technology consists in using the MRI RF coils both for receiving the MR signal and for injecting a DC current in order to spatially-modulate the static magnetic field in the desired region (Stockmann et al., 2016). Because of their low inductance, these so-called "AC-DC" coils can also be used to perform dynamic shimming while producing minimum Eddy-currents (when compared to the large shim coils integrated in the MR system).

Dynamic shimming consists in rapidly changing the shim coefficients for each slice independently. Hence, instead of trying to find a fixed set of coefficients that minimizes inhomogeneity in an entire volume, with dynamic shimming this estimation is done on a per-slice basis. Dynamic shimming is particularly interesting for acquisitions with a large number of slices covering a large region hampered by susceptibility variations: the brain-spine axis is a perfect example. However, it can be difficult to find the right combination of XYZ shim currents in a small region such as the spinal cord. Typically, spinal cord fMRI acquisition is done axially with thick (3-5mm) slices. In this case, the strongest effect of gradient inhomogeneity is along the Z direction (superior-inferior axis), hence previous studies have proposed to only correct for this gradient, naming this approach z-shimming (Finsterbusch et al., 2012; Islam et al., 2019). This technique has shown substantial improvement in image quality for gradient-echo EPI, notably the reduction of signal dropout which is typically observed at the vicinity of intervertebral discs. For more details on shimming strategies for the spinal cord see Finsterbusch (2014).

Another important effect is that B0 inhomogeneity also varies with subject breathing. This effect is particularly problematic when imaging close to the lungs, e.g. around vertebral levels C7-T1. B0 variation can be about 70 Hz at 3T (Verma and Cohen-Adad, 2014) and 110 Hz at 7T (Vannesjo et al., 2017), causing voxel displacement in EPI readout and ghosting in EPI and line-scan gradient-echo imaging. To tackle this issue, real-time shimming can be used, which consists in varying the shimming setup along with subject's breathing, as was demonstrated in the brain at 7T (Gelderen et al., 2007) and spinal cord at 3T (Topfer et al., 2018). All these advanced techniques are being actively developed, so there is hope that vendors will rapidly translate some of these innovations into widely-available products.

3.1.4. Subject positioning and passive shimming

Careful positioning of the subject can have an impact on the overall image quality. In general, it is desirable to have the cervical cord almost straight so that axial slices are orthogonal to the cord centerline, which minimizes partial volume effects with the surrounding cerebrospinal fluid. To minimize the cervical lordosis subject can be asked to slightly tilt their head towards their chin. They should however not be too uncomfortable and still be able to swallow while producing minimum motion - it is always a good idea to show the subject how to properly swallow before starting an acquisition. Some hints are described in the standard operating procedure of the spinal cord generic protocol (Cohen-Adad, 2020).

Reducing neck curvature also helps improve field homogeneity because the shim volume (i.e., the 3D box centered over the region of interest where the MR system computes the optimal shim coefficients) is less likely to contain air-tissue interfaces. An alternative (but not mutually-exclusive) way to reduce the effect of the air-tissue interfaces below the neck is to add a cushion filled with a material that has similar susceptibility than the tissue. Examples of such material include perfluorocarbon, barium sulfate-doped water, Kaopectate and pyrolytic graphite (PG)-doped foam. Fig. 3B shows how PG foam located behind the neck can minimize B0 field inhomogeneities around the spine region.

3.1.5. Radiofrequency (RF) shimming

The previous section talked about the importance of a homogeneous static (B0) magnetic field, but a homogeneous RF field is important as well. Also called B1+, this field corresponds to the RF energy sent by the transmit coils during the excitation phase of a pulse sequence, aiming at flipping the spins towards the transverse plane (a.k.a. the flip angle). When B1+ field is not homogeneous, the requested flip angle is not equal across the entire imaging region, introducing spatially-variable contrast and SNR, which can affect fMRI statistical analyses. In spine imaging, B1+ homogeneity is hampered by the presence of tissues with different electrical conductivity and permittivity (Barry et al., 2018; Guy, 1971). Moreover, in brain-spine studies, the imaging region is relatively large, making it more difficult to obtain a homogeneous B1+ across the entire imaged region. On 3T systems, excitation is typically performed using the integrated body coil, ensuring a homogeneous B1+ field, so this effect is generally not discussed much. However at 7T and higher, the RF wavelength is shorter and B1+ becomes dramatically less homogeneous. In addition, transmit coils are smaller and closer to the imaged tissue, therefore RF shimming strategies become more important (Eryaman et al., 2015; Henning et al., 2016; Kraff et al., 2009).

3.1.6. Pulse sequence

In addition to dedicated hardware (magnet, RF and shim coils), optimizing the pulse sequence is an effective way of reducing susceptibility artifacts, imaging faster and improving image quality in general. A good rule of thumb when it comes to minimizing susceptibility artifacts is to

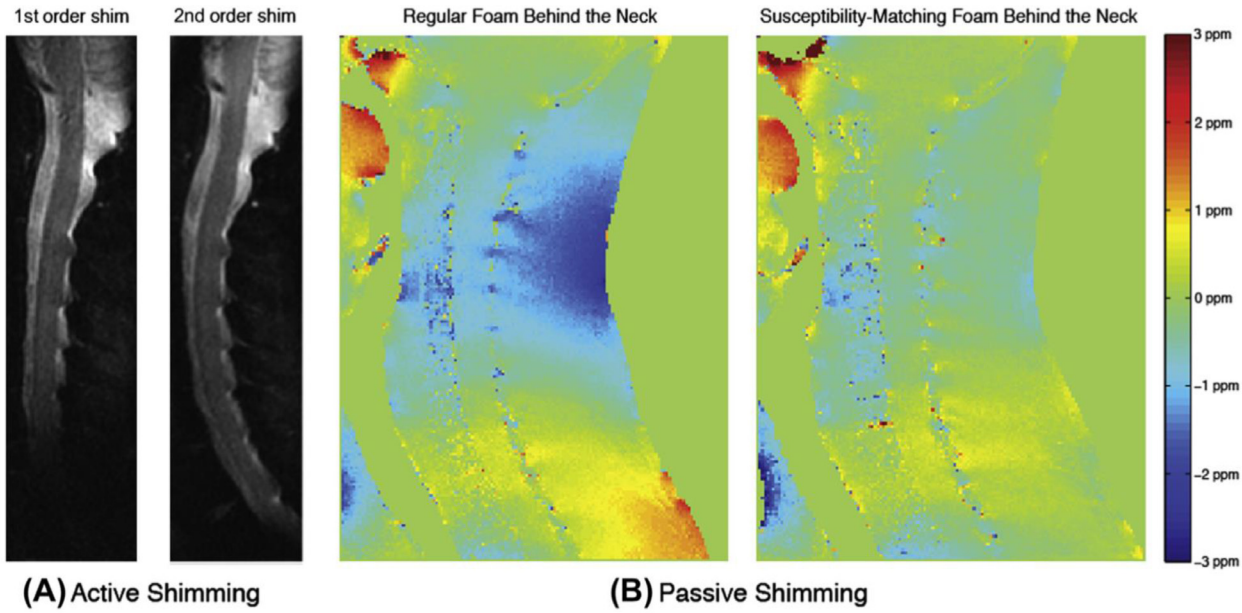

Fig. 3. Effects of different shimming strategies on susceptibility artifacts. (**A**) T2-weighted reduced-FOV ss-EPI images of the spinal cord, acquired at 3T, with first-order (i.e., only the linear gradients) shim versus second-order shim (gradients + shim coils). Note the improvement in distortions and the signal intensity, especially towards the upper thoracic cord using higher order shimming. (**B**) Field maps of the neck acquired with regular foam versus susceptibility-matching foam placed behind the neck. With the susceptibility-matching foam, the air volume in the back of the neck is filled with a material that has the same magnetic susceptibility as that of human tissue. Hence, the B0 field inhomogeneities are drastically reduced. Reproduced with permission from Saritas and colleagues (2014).

acquire the EPI k-space faster using reduced field-of-view techniques, via parallel acquisition or selective 2D-RF excitation (to prevent aliasing along the phase-encoding direction). For more information on EPI techniques that minimizes distortions, the reader is referred to Saritas and colleagues (2014).

Alternatively, some researchers have explored non-EPI sequences that provide better image quality (Bosma and Stroman, 2015) however at the cost of lower sensitivity and longer acquisition times (Bouwman et al., 2008; Jochimsen et al., 2005; Moffitt et al., 2005). A representative example of pulse sequence parameters employed for simultaneous coverage of the brain and cervical spine is listed in Table 1 and some geometric setups are illustrated in Fig. 4.

3.2. Image analysis techniques

3.2.1. Distortion correction

Despite all the techniques mentioned above, residual distortions are likely to exist in fMRI data. To correct them, one can use B0 field maps, blip-up/blip-down scans or registration to a non-distorted image with similar contrast (e.g. anatomical T2w or T2*w scan). More details are available in (Snoussi et al., 2019; Voss et al., 2006).

3.2.2. Motion correction

FMRI datasets consist of a collection of multiple volumes whose number can range from 10–20 to several hundreds. This data usually takes several minutes to acquire. If the subject moves between volumes, this can compromise the voxel-wise analysis done on the whole dataset. It is thus a common procedure to perform rigid body motion correction, which consists in registering all volumes to a target volume (e.g., first or average in a two-pass procedure). Unfortunately, the spine is an articulated structure, which can lead to non-linear displacements. Therefore standard brain motion-correction algorithms assuming rigid or affine transformation are more error prone. Consequently, alternative approaches have been established such as correcting slice-wise translations in the axial plane (De Leener et al., 2017; Duval et al., 2015; Grussu et al., 2015; Iglesias et al., 2015; Kong et al., 2012; Mohammadi et al., 2013; Xu et al., 2013). The slice-wise analysis is however less robust, therefore regularization along the superior-inferior (Z) axis is usually implemented in these approaches.

3.2.3. Slice timing correction

Each volume of an fMRI time series consists of several 2D slices, each being acquired at a different time (except in the case of 3D acquisition). When performing traditional fMRI statistical analysis, each volume is considered being acquired at the same ("single") time point, in which case the timing of each slice needs to be adjusted. This operation is called "slice timing correction" and consists in interpolating the time series of voxels in the time dimension to bring all of them in-phase across the entire volume. Depending on the sampling interval (TR) this can result in considerable temporal smoothing of the signal. With regard to brain fMRI, several studies have shown beneficial effects of slice timing correction on group inferences (Parker and Razlighi, 2019; Sladky et al., 2011) and some spinal fMRI studies performed slice timing correction (Islam et al., 2019; Vahdat et al., 2020; Weber et al., 2016a). However, it has also been shown that slice timing correction biases the estimation of motion between volumes in cases of excessive movement leading to the underestimation of real motion and suboptimal motion correction (Power et al., 2017). Therefore, slice time correction within the spinal cord with its high signal fluctuations and physiological noise related movement might not be beneficial and might even increase the bias in the spinal signal. Another problem that arises from slice timing correction is that it is particularly needed in studies with a long TR (like in HASTE-based acquisition (Ioachim et al., 2019)) but at the same time it increases information loss with increasing TRs because of its temporal smoothing properties. Based on the Nyquist theorem, aliasing, i.e. information loss occurs if the sampling frequency is smaller than twice the frequency of the signal of interest. Applying slice timing correction to an aliased signal would therefore increase the error within the signal of interest instead of correcting it for different acquisition times. Further research has to elaborate if and for which repetition times slice timing correction is beneficial with regard to spinal fMRI data. One solution to circumvent the slice timing correction problem is to use a slice specific

Table 1
Pulse sequence parameters and their respective pros and cons for different approaches to cover the brain(stem) and spinal cord. Every approach is listed with their first and most recent publication if applicable. Please note that the TR per slice for pulse sequences with two subvolumes indicates an averaged acquisition time although the TR per slice might differ between the brain and spinal cord. SI - superior-inferior; RL - right-left

Study	Scanner	Coverage	Sequence	Orientation	Resolution	TR (TR per slice)	Pros	Cons
Stroman et al., 2008	Siemens Trio	Brainstem and spinal cord C1 to C7/T1 14 slices	HASTE	sagittal	One volume 1 × 1 × 2 mm (no gap)	14 s (~1000 ms)	• Spatial resolution in SI-direction • Distortion-free	• Temporal resolution • Spatial resolution in RL-direction • No cortical or subcortical coverage except brainstem • Less sensitive to BOLD signal
Ioachim et al., 2019	Siemens Trio	Brainstem and spinal cord C1 to C7/T1 9 slices	HASTE	sagittal	One volume 1.5 × 1.5 × 2 mm (no gap)	6.75 s (~750 ms)	• Spatial resolution in SI-direction • Distortion-free	• Temporal resolution • Spatial resolution in RL-direction • No cortical or subcortical coverage except brainstem • Less sensitive to BOLD signal
Cohen-Adad et al., 2010	Siemens Trio	Brain and spinal cord C1 to C7 30 slices	EPI	axial	One volume 1.5 × 1.5 × 4 mm (4.4 - 5.2 mm gap)	3 s (~100 ms)	• Temporal resolution • Spatial resolution in axial plane • Large volume	• Spatial resolution in SI-direction • One set of shimming parameters for entire volume
Vahdat et al., 2015	Siemens Trio	Brain and spinal cord C1 to C7 35-37 slices	EPI	axial	One volume 2.5 × 2.5 × 4 mm (3.2 - 4.8 mm gap)	2.5 s (~70 ms)	• Temporal resolution • Large volume	• Spatial resolution • One set of shimming parameters for entire volume
Finsterbusch et al., 2013	Siemens Trio	Brain and spinal cord C4 to C6 32 + 8 slices	EPI	axial	Two subvolumes *Brain:* 2 × 2 × 2 mm (1 mm gap) *Spinal:* 1 × 1 × 5 mm	3.27 s (~80 ms)	• Temporal resolution • Spatial resolution • Different geometric resolutions and timings for brain and spinal cord	• Finding optimal shim parameters time costly (~30 minutes)
Tinnermann et al., 2017	Siemens Trio	Brain and spinal cord C4 to C6 33 + 12 slices	EPI	axial	Two subvolumes *Brain:* 2 × 2 × 2 mm (1 mm gap) *Spinal:* 1.25 × 1.25 × 3.5 mm	2.99 s (~70 ms)	• Temporal resolution • Spatial resolution • Different geometric resolutions and timings for brain and spinal cord	• Finding optimal shim parameters time costly (~30 minutes)
Islam et al., 2019	GE Discovery 750	Brain and spinal cord C4 to C8 18 + 12 slice	EPI	axial	Two subvolumes *Brain:* 3.4 × 3.4 × 4 mm *Spinal:* 1.25 × 1.25 × 4 mm (2 mm gap, b + sp)	2.4 s (~80 ms)	• Temporal resolution • Spatial resolution in spinal axial plane • Different geometric resolutions for brain and spinal cord • Field map based slice-specific shim • Reduced FOV in spinal cord	• Spatial resolution in the brain

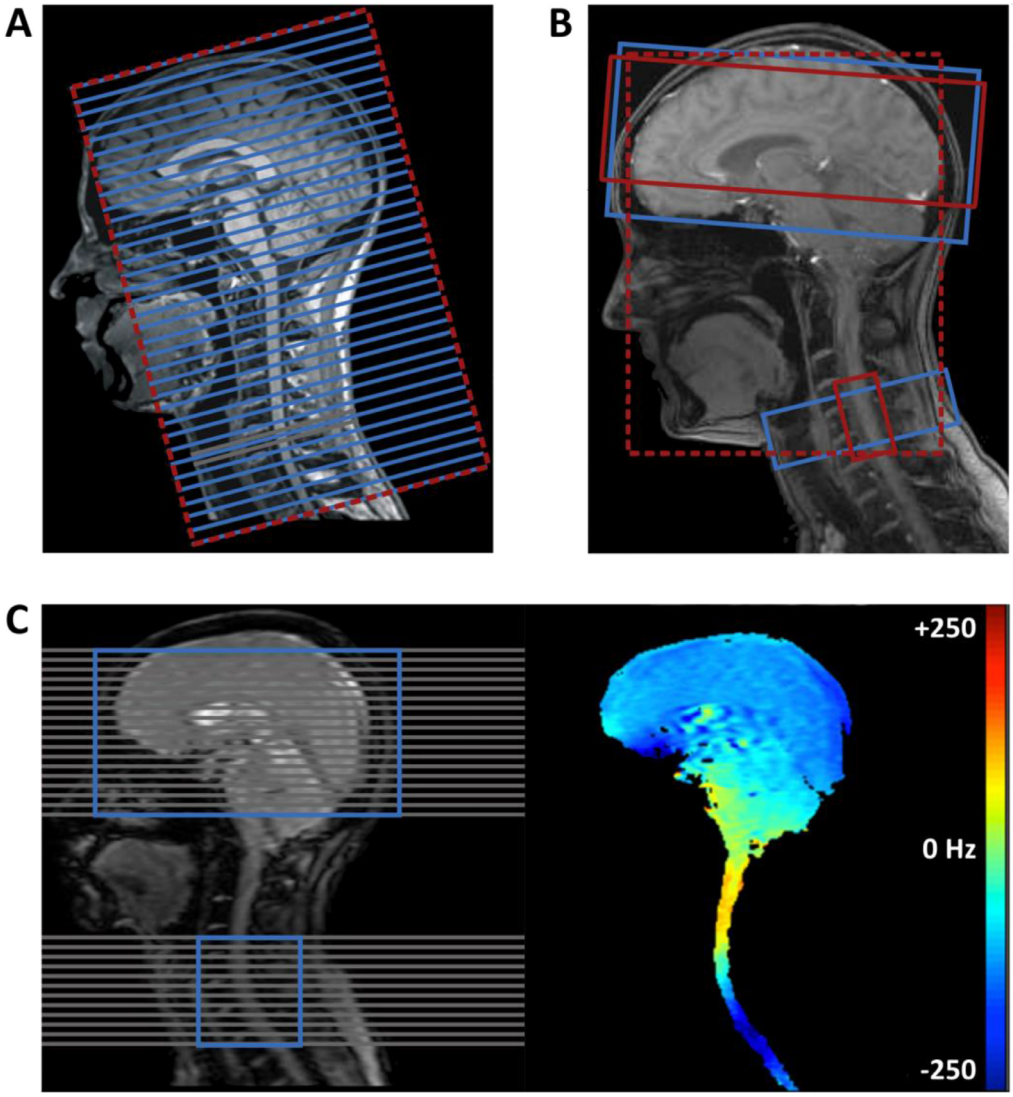

Fig. 4. Geometric setup for three different cortico-spinal imaging approaches. The figures are adapted from Vahdat et al. (2015), Finsterbusch et al. (2013) and Islam et al. (2019). (**A**) The approach by Cohen-Adad et al. (2010) involves one large FOV (blue) and adjustment volume (dotted red) covering the entire brain and cervical spinal cord using a large gap between slices. (**B**) The approach by Finsterbusch et al. (2013) comprises two different FOVs with different resolutions in the brain and cervical spinal cord (blue) and three shim adjustment volumes, one in brain, one in the spinal cord (red) and one covering both subvolumes (dotted red). (**C**) Left: The approach by Islam et al. (2019) involves two FOVs in the brain and cervical spinal cord (blue) with different resolutions. The slice position is indicated in gray. Right: Instead of adjustment volumes, a slice-specific shim is calculated based on field maps.

design matrix or temporal derivatives in single-subject statistical models to account for different acquisition times between slices as has been realized in previous studies (Kong et al., 2012; Weber et al., 2016b).

3.2.4. Smoothing

Spatial smoothing is a common pre-processing step in brain fMRI analysis with the aim to increase the SNR and to account for anatomical differences in brain structures between individuals. Usually a smoothing kernel with a full width at half maximum (FWHM) of two to three times the voxel size in all three dimensions is applied. Since the spinal cord is a small structure that is anatomically more homogenous than the brain, spatial smoothing recommendations differ for the spinal cord. The cross-sectional size of the spinal cord between C4 and C6 vertebrae measured on the PAM50 template (average across 50 healthy adults) is approximately 13 mm in right-left and 9 mm in anterior-posterior orientation. Moreover, the internal structure, such as the gray matter, is only about 16 mm^2 (Paquin et al., 2017), and some of its parts, like the dorsal horn, can be thinner than a millimeter. Therefore, using smoothing kernels of several millimeters (at least in the x or y dimension) if the activation cluster is only sub-millimetric can flood the apparent BOLD signal, if its point spread function is narrow, as illustrated in Fig. 5A. This can become problematic for the identification of lateralized activation in the context of pain when stimulating one limb. Another problem is that the spinal cord gray matter is surrounded by white matter and CSF. This bears the risk of smoothing signals with high noise into the gray matter signal. Finally, spinal cord fMRI acquisition typically uses highly anisotropic voxels, e.g. $1 \times 1 \times 5$ mm with axial orientation, therefore isotropic smoothing kernels should be avoided. Based on the above observations, it has been recommended to use anisotropic smoothing kernels, with a small FWHM in the axial plane (in case of axial acquisitions) to preserve anatomical precision and larger FWHM along the inferior-superior axis to increase the SNR (Eippert et al., 2017a). Combined cortico-spinal imaging studies that used two separate fields of views, applied different smoothing kernels for the brain and spinal cord (Sprenger et al., 2015; Tinnermann et al., 2017) while only one study applied an anisotropic kernel in the spinal cord (Islam et al., 2019). Since

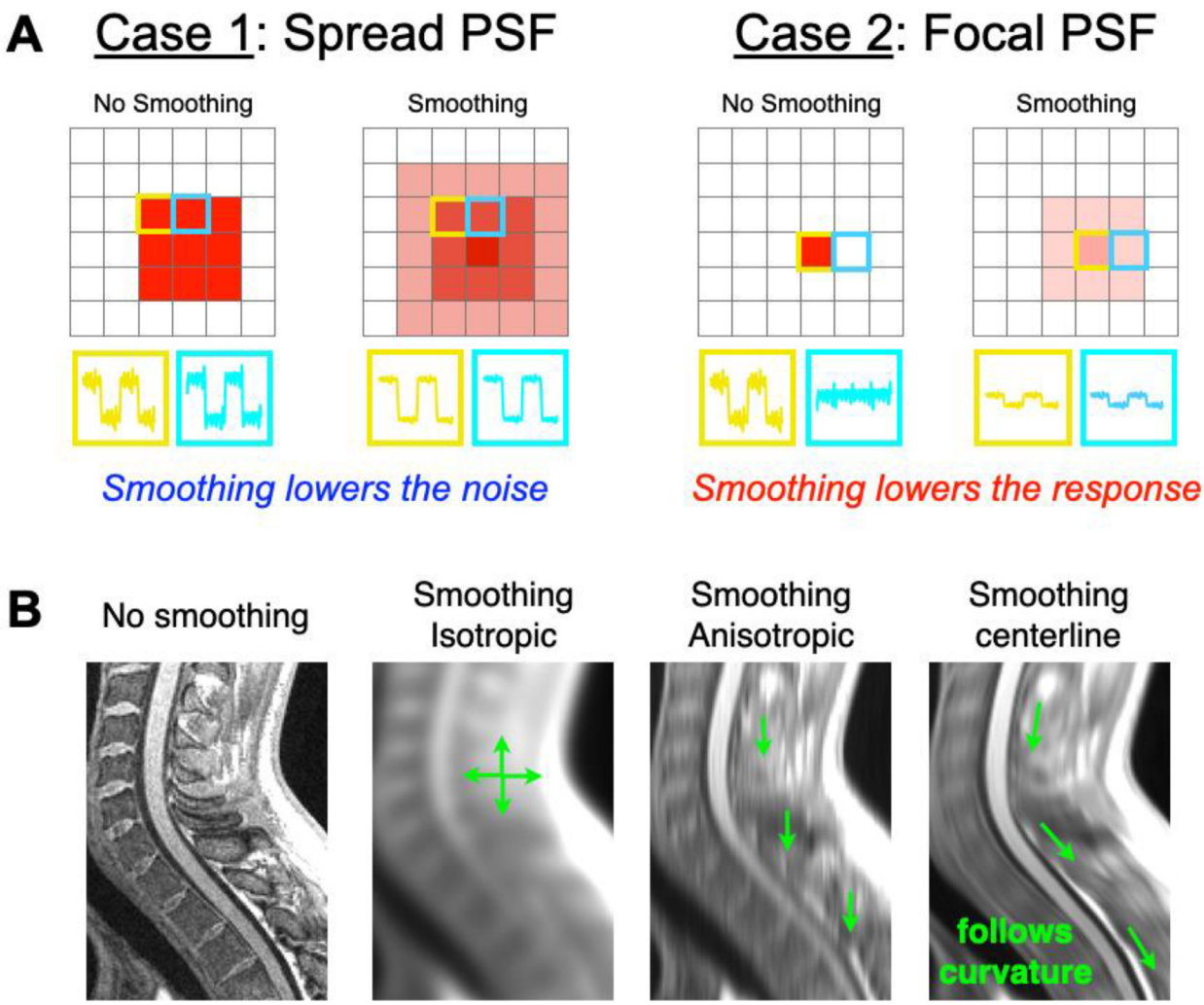

Fig. 5. (**A**): Illustration of the smoothing problem. In case 1, the point spread function (PSF) of the BOLD signal is large, in which case smoothing (at a reasonable kernel size) will increase the contrast-to-noise ratio of the BOLD response. In case 2, the PSF is narrow, and smoothing could flood the BOLD response and lower its detectability. Adapted with permission from (Summers et al., 2014). (**B**): Illustration of the effect of isotropic, anisotropic and centerline-based smoothing. While the anisotropic smoothing enables to minimize partial volume effect with the surrounding CSF when the cord is aligned with the major axis of the smoothing kernel, smoothing is inconsistent if the cord is curved. Centerline-based smoothing addresses this problem by applying the same smoothing kernel along the spinal cord centerline referencial system, thereby better preserving its anatomical consistency.

the length of spinal segments that correspond to dermatomes C5 and C6 and which are often stimulated in pain studies are estimated to measure between 10 and 13 mm (Cadotte et al., 2015; Kim et al., 2012), approaches with large voxel sizes along the z (inferior-superior) axis and a gap between slices might run into issues with anatomical precision with regard to spinal segments.

One problem with anisotropic smoothing described above, is that the amount of partial volume effect with the surrounding white matter and CSF introduced by the smoothing kernel depends on the curvature of the spinal cord. For example, one individual exhibiting strong cord curvature will be subject to more partial voluming than an individual with a straight cord orthogonal to the slices. To address this issue, the Spinal Cord Toolbox (SCT) (De Leener et al., 2017) features spatial smoothing along the spinal cord centerline, as illustrated in Fig. 5B. This feature was notably used by Weber and colleagues to look at spinal cord activity during thermal stimulation (Weber et al., 2016b).

3.2.5. Physiological noise correction

Apart from subject motion, pulsatile cerebrospinal fluid (CSF) fluctuations due to breathing and cardiac activity create non-rigid motion artifacts within the spinal cord that cannot be accounted for by motion correction algorithms (Eippert et al., 2017a; Kong et al., 2012; Piché et al., 2009). The presence of this physiological noise in spinal data requires noise correction methods that are customized for the spinal cord. To account for cardiac and respiratory cycles, physiological noise modeling (Brooks et al., 2008) has been proposed to correct for physiological noise based on either the RETROICOR (Glover et al., 2000) or Deckers (Deckers et al., 2006) method. In order to apply physiological noise modeling, cardiac and respiratory data have to be acquired through a pulse-oximeter and a respiration belt. These approaches allow the estimation of nuisance regressors that can be included in statistical analyses and which have been implemented in several cortico-spinal studies (Sprenger et al., 2018; Tinnermann et al., 2017; Vahdat et al., 2020). Another possibility to remove physiological noise from the spinal data is via independent component analysis (Piché et al., 2009; Vahdat et al., 2015). Other approaches that do not rely on the recording of cardiac and respiratory signals, define regions of interest that do not contribute to the signal of interest within the CSF and white matter and extract the signal from these regions as nuisance regressors. This has been realized by averaging the signal within the region of interest (Ioachim et al., 2019;

Vahdat et al., 2020, 2015) and by defining components of the signal that explain high variance employing a principal component analysis across volumes (Tinnermann et al., 2017) or across axial slices (Barry et al., 2016, 2014). For a more detailed description of physiological noise correction in spinal cord fMRI data, the reader is referred to the review by Eippert and colleagues (2017a) .

3.2.6. Statistical analyses

Because of different noise levels between the brain and the spinal cord, we do not recommend analysing brain and spinal data within the same General Linear Model (GLM). Instead, brain and spinal data should be analyzed separately as has been done in most combined cortico-spinal imaging studies. This approach has several advantages: First, different pre-processing steps can be applied to brain and spinal data based on different requirements and second, different nuisance regressors can be applied to the spinal GLM than to the brain GLM to account for different (physiological) noise levels. If experimental regressors are kept identical in both GLMs, it is possible to run the same statistical model on brain and spinal data while this approach would not allow to run statistical comparisons between the brain and spinal cord. Nonetheless, it is crucial to apply appropriate multiple comparisons correction to spinal group analyses, similar to brain group analyses in order to increase reliability of spinal fMRI results. One possibility for hypothesis-driven multiple comparisons correction is to use anatomical masks (e.g. gray matter) that are provided by SCT or (if possible) averaged coordinates from previous spinal fMRI studies which requires standardized reporting of activation maps in e.g. MNI space. For more information on statistical recommendations for spinal group statistics, the reader is referred to (Brooks, 2014).

Concerning connectivity analyses, several approaches such as independent component analysis or psychophysiological interaction rely on correlations between time courses. These approaches should not be affected by the different SNRs between brain and spinal cord when correlating spinal with brain time courses. Other connectivity approaches such as dynamic causal modeling are more sensitive to varying noise levels between regions of interest and should therefore be applied with caution.

With regard to single-subject statistical analyses, consistent motor-related single-subject activation has been reported in the spinal cord (Islam et al., 2019; Weber et al., 2016a) as well as consistent single-subject resting-state connectivity (Barry et al., 2014). In the field of pain research, a few studies have shown that single-subject results can be consistent with group-level results (Summers et al., 2010; Weber et al., 2016a). However, another study in patients with spinal cord injury has shown large variations in nociceptive processing within the spinal cord (Stroman et al., 2016b). Furthermore, because of the low (t)SNR in the spinal cord, single-subject results should be interpreted with caution.

3.2.7. Template and registration strategies

Group-level fMRI analyses typically follows a 2-step approach: first, fMRI data of a single subject are processed and then statistical maps are warped to a template space via the anatomical image (usually a T1w MPRAGE sequence), then data from all subjects are processed within the same template space to derive voxel-wise group-level statistical maps. This approach, when applied to the spinal cord, requires a template and a robust method to register subject's data to this template.

Several research groups have proposed MRI templates of the spinal cord. Stroman et al. (Stroman et al., 2008) created a template (n=8 subjects) based on 1 × 1 × 2 mm T2-weighted (T2w) fast-spin echo images for use in functional MRI studies. The authors later extended this template to 10 subjects and introduced a normalization approach based on the distance from the pontomedullary junction (PMJ) to obtain an improved representation of the spinal levels (Stroman et al., 2012). The same group later used a similar approach to generate a T2w template of the brainstem and cervical spinal cord (n=356) (Bosma and Stroman, 2014). Valsasina and colleagues (2012) proposed a normalization procedure based on a semi-automated segmentation approach to generate a T1-weighted template (n=19) of the cervical spinal cord. Another group built a template (n=15) out of T1-weighted cervical cord images (Eippert et al., 2009b), with the limitation that this template was created by arbitrarily selecting one subject that served as a target for registering all the other subjects. To address the issue of subject selection bias during template generation, Fonov and colleagues (2014) used template-generation pipelines similar to that used for creating the MNI template and introduced the MNI-Poly-AMU, an unbiased template (n=16) based on T2w data, that also includes probabilistic atlases of the white and gray matter from Taso and colleagues (2014). One limitation of the MNI-Poly-AMU is that it only covers vertebral levels C1 to T6 and is only available with T2-weighted contrast. To overcome this limitation, the same group later introduced the PAM50 template (n=50), which is left-right symmetric and unbiased with respect to subject selection, covers the full spinal cord and brainstem, is available for commonly used MRI contrasts (T1-w, T2-w and T2*-w), is merged with probabilistic maps atlases of the spinal cord white and gray matter (Lévy et al., 2015) and uses the same coordinate system as the ICBM-152 "MNI" brain space (Fonov et al., 2011), facilitating the analysis of simultaneous cortico-spinal imaging studies. The PAM50 template is available via SCT (De Leener et al., 2017). Alternatively, Blaiotta and colleagues (2018) have introduced a combined brain and cervical cord template that can be used in the hMRI toolbox (Tabelow et al., 2019) which is based on SPM12, and which allows to segment and to spatially normalize brain and cervical cord MRI data (https://www.fil.ion.ucl.ac.uk/spm/toolbox/TPM/).

3.2.8. Software package for spinal cord MRI analysis

While templates are extremely useful for group studies, they only represent part of the solution, the other part being the registration method and software implementation to use these templates. At the beginning of the spinal cord fMRI era, researchers were using popular packages (e.g., FSL, SPM, AFNI), with the limitation that some algorithms were suboptimal for the spinal cord (e.g., motion correction, co-registration, template and atlases). To bridge the gap, Stroman and colleagues have introduced spinalfmri8, which is a free software package dedicated to the analysis of spinal cord fMRI data (http://post.queensu.ca/~stromanp/software.html). In brief, registration of a new subject to the provided template is based on a spatial normalization using 3D alignment, based on the spinal cord centerline (manually-identified) and linear transformation. An alternative software package mentioned above is based on SPM12 and features the brain and cervical spine template of Blaiotta and colleagues (2018). This implementation can be used to register new subjects to this template using algorithms of the SPM12 software. SCT is another software package (https://spinalcordtoolbox.com/) (De Leener et al., 2017) that is a comprehensive, free and open-source software dedicated to the processing and analysis of spinal cord MRI data. SCT builds on previously-validated methods and includes previously mentioned MRI templates and atlases of the spinal cord, algorithms to segment and register new data to the templates, and motion correction methods for diffusion and functional imaging time series. SCT is tailored towards standardization and automation of the processing pipeline, versatility, modularity, and it follows the guidelines of software development, distribution, maintenance and user support via annual courses and dedicated forum (http://forum.spinalcordmri.org/c/sct). SCT has been used in many spinal cord fMRI studies (Eippert et al., 2017b, 2017a; Kinany et al., 2019; Kong et al., 2014; Weber et al., 2018, 2016b, 2016a). Fig. 6 illustrates an end-to-end processing of anatomical and fMRI data in SCT. A list of software packages dedicated to spinal cord MRI is maintained at this address: https://spinalcordmri.org/software/.

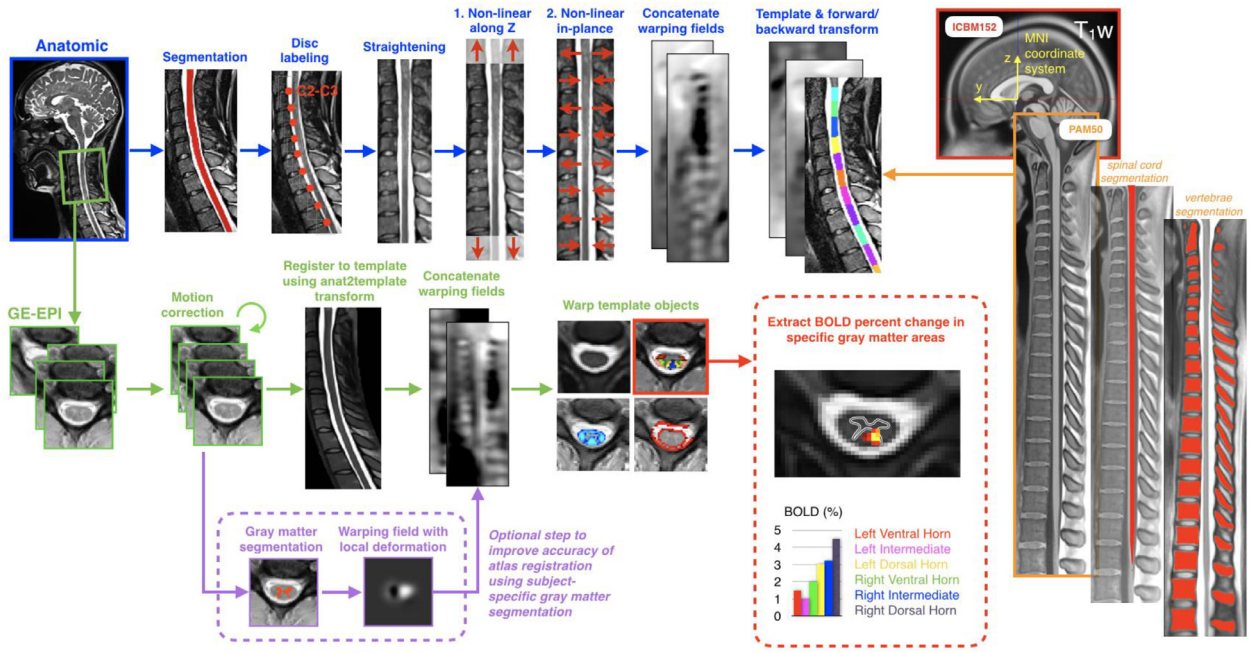

Fig. 6. Overview of a template-based analysis pipeline using SCT. On the far right the PAM50 spinal cord template (orange box) and the MNI brain template (red box) are shown. First, anatomical data (e.g., T1w or T2w scan at 1 mm isotropic resolution or similar) is registered to the template (blue arrows). Additional fMRI time series acquired during the same scan session are registered to the anatomical data, and then template objects are warped to the multi-parametric data (green arrows). To improve the accuracy of template registration, it is possible to add a step where grey matter is segmented (Perone et al., 2018) and then warped to the grey matter template in order to update the warping fields (purple arrows). Subsequently, fMRI maps (e.g., BOLD percent change) can be quantified within specific gray matter areas and vertebral levels that are deemed relevant for the study (red arrows).

4. Potential applications of cortico-spinal imaging in pain research

4.1. Chronic pain states

One crucial aim of pain research is the characterization and understanding of altered pain processing in chronic pain patients. Central sensitization is considered to be an important contributor in chronic pain states that leads to hyperalgesia and allodynia, i.e. heightened responses to painful stimuli and to non-painful stimuli, respectively (Kuner, 2010; Sandkühler, 2009; Woolf, 2011). Hence, when exposed to experimental pain, chronic pain patients report increased pain levels and show increased activity in pain-related brain regions compared to healthy controls (Cook et al., 2004; Giesecke et al., 2004; Verne et al., 2003). In line with this observation, activity within regions of the Neurological Pain Signature in response to experimental pain has been shown to be increased in chronic pain patients (López-Solà et al., 2017). Furthermore, a spinal fMRI study has shown that activity in the dorsal horn was increased in pain patients in response to noxious stimulation (Bosma et al., 2016) suggesting that spinal nociceptive processing is increased in chronic pain states. In addition, there is evidence that modulatory pain processes are impaired in chronic pain patients (Bouwense et al., 2013; Jarrett et al., 2014; Williams et al., 2013) and that patients show reduced functional coupling between the pgACC and PAG (Jensen et al., 2012). However, when chronic pain patients experience clinical pain in comparison to experimental pain, activations were observed rather in prefrontal than classical pain-related brain regions (Baliki et al., 2006; Gwilym et al., 2009; Hsieh et al., 1995; Schweinhardt et al., 2008). In line with these findings, acute pain patients that transition to a persistent pain state also show a shift in activation patterns from pain-related brain regions to mainly prefrontal brain regions (Hashmi et al., 2013). Moreover, it has been observed that connectivity between prefrontal cortex and basal ganglia can predict whether acute pain patients transition to a chronic pain state (Baliki et al., 2012). These findings indicate that chronic pain patients engage more affective than somatosensory brain areas while experiencing clinical pain. In this regard, simultaneous cortico-spinal imaging has the potential to disentangle different circuits that underlie altered processing in chronic pain states by investigating interactions between the spinal cord and brain regions of ascending and descending pain pathways.

4.2. Intrinsic connectivity

Studies in healthy participants have shown that intrinsic connectivity such as resting-state functional connectivity can predict pain sensitivity (Spisak et al., 2020) and that noxious stimulation can modulate these intrinsic connectivity networks within the brain (Riedl et al., 2011; Zheng et al., 2019). Importantly, studies have shown that intrinsic connectivity can help to distinguish healthy participants from chronic pain patients (Mano et al., 2018; Mansour et al., 2016), which led to an increased focus on intrinsic connectivity in chronic pain states (Kucyi and Davis, 2015). One consistent finding is that the default-mode network (DMN), a network that usually shows crosstalk during rest, shows altered functional connectivity in chronic pain patients (Baliki et al., 2014; Kucyi et al., 2014; Napadow et al., 2010). Moreover, compared to healthy controls, the DMN shows altered connectivity with other brain regions such as the insula and prefrontal cortex (Baliki et al., 2014; Loggia et al., 2013; Napadow et al., 2010; Tagliazucchi et al., 2010; Xue et al., 2012) as well as with other intrinsic networks (Hemington et al., 2016). In longitudinal studies, intrinsic connectivity during the initial measurement was able to predict if patients' symptoms would improve over the course of the study (Kutch et al., 2017; Schmidt-Wilcke et al., 2014). Apart from the DMN, intrinsic connectivity has been studied within pain-related brain regions in patient samples. For example, chronic pain patients showed reduced resting-state connectivity along the descending pain pathway (Li et al., 2016; Mainero et al., 2011), which was reversed through pain treatments (Li et al., 2016). These findings further indicate that descending modulation might be impaired in chronic pain states.

With advances in spinal cord fMRI imaging, the possibility to investigate intrinsic connectivity within the spinal cord emerged (San Emeterio Nateras et al., 2015; Wei et al., 2009). Several studies have identified potentially distinct sensory and motor networks within dorsal and ventral horns (Barry et al., 2016, 2014; Eippert et al., 2017b; Kong et al., 2014). Intrinsic connectivity in bilateral sensory networks of spinal dorsal horns has been shown to be decreased after noxious stimulation (Weber et al., 2018) and in chronic pain patients (Martucci et al., 2019). Combining the investigation of intrinsic connectivity in the brain and spinal cord is therefore expected to help broaden the understanding of how networks on different levels might be altered in chronic pain states. A first step in that direction has recently been published where researchers were able to show intrinsic connectivity between the spinal cord dorsal horn and pain-related brain regions (Vahdat et al., 2020) .

4.3. Pharmacological pain modulation

Several pharmacological classes are available for the treatment of pain, such as opioids, cyclooxygenase inhibitors, anticonvulsants and ketamine (Oertel and Lötsch, 2013). Opioids such as morphine are potent analgesics, which bind to opioid receptors that are distributed throughout the entire central nervous system. High opioid receptor densities are found in regions that are part of the pain-processing network such as the spinal cord, RVM, PAG, insula, somatosensory cortex, MCC (dACC) and prefrontal cortex (Corder et al., 2018). In line with the distribution of these receptors, fMRI studies investigating opioid-receptor agonist effects in the brain of healthy participants consistently found reductions in BOLD responses during noxious stimulation in pain-related brain regions such as the somatosensory cortex, insula and ACC, together with reported analgesia (Atlas et al., 2012; Bingel et al., 2011; Hansen et al., 2015; Oertel et al., 2008; Wise et al., 2004, 2002). Furthermore, opioid analgesia has been shown to correlate with opioid-induced BOLD reductions in regions of the descending pain system such as the PAG and RVM (Wanigasekera et al., 2012). Other pharmacological classes that were not primarily developed as analgesics have been found to also display analgesic effects, such as anticonvulsants and ketamine. Anticonvulsants such as gabapentin reduce pain perception and activity in pain-related brain regions in chronic pain patients (Iannetti et al., 2005; Wanigasekera et al., 2018) while ketamine has been shown to effectively reduce pain and pain-related activity in healthy participants (Rogers et al., 2004; Sprenger et al., 2006). Conversely, agents that do not show a clear analgesic effect across different chronic pain conditions, such as cannabinoids, NK1-receptor antagonists or tricyclic antidepressants, have been shown to reduce activity in brain regions that are not primarily pain-related (Lee et al., 2013; Morgan et al., 2005; Upadhyay et al., 2011). In order to identify agents that are promising for pain treatment in early stages of clinical trials, it has been suggested to assess BOLD activity in response to new drugs (Borsook et al., 2006; Carmichael et al., 2018; Wise and Tracey, 2006). To implement this idea, one study developed criteria based on brain activation patterns from different fMRI studies investigating analgesic drugs to make Go/Stop decisions in an early phase of a clinical trial (Duff et al., 2015). Extending this approach, cortico-spinal imaging could further improve the understanding of pharmacological mechanisms and improve predictions regarding clinical efficiency in new analgesic drugs.

4.4. Descending pain modulation

Another important aspect of pain processing is the modulation of nociceptive information and its implementation in the central pain system. Although pain perception increases monotonically with stimulus intensity (Bornhövd et al., 2002; Coghill et al., 1999; Horing et al., 2019; Wager et al., 2013), cognitive factors such as attention, anxiety, expectations or prior experiences are known to influence how pain is perceived (Tracey and Mantyh, 2007). For example, being distracted from a painful stimulus by a cognitively demanding task reduced pain perception in healthy participants (Bantick et al., 2002; Buhle et al., 2012; Sprenger et al., 2012). Moreover, verbal instructions suggesting subsequent pain relief paired with an inert medical treatment can establish expectations that lead to placebo hypoalgesia (Montgomery and Kirsch, 1997) whereas suggestions about pain increase paired with an inert medical treatment can establish expectations that lead to nocebo hyperalgesia (Benedetti et al., 2006, 1997). Neuroimaging studies of the brain have revealed that regions of the descending pain pathway are involved in pain modulation. For instance, distraction from noxious stimulation resulted in increased activity in the pgACC (Bantick et al., 2002). Similarly, placebo hypoalgesia is accompanied by increased activations in the pgACC and vmPFC and placebo effects have been found to correlate with activity in prefrontal brain regions (Wager and Atlas, 2015). Within the brainstem, increased activity in the PAG has been reported in several studies in relation to placebo hypoalgesia (Eippert et al., 2009a; Geuter et al., 2013; Scott et al., 2008; Wager et al., 2004). In line with these observations, neural coupling along the descending pain pathway between prefrontal cortex and brainstem has been shown to be increased both during distraction (Valet et al., 2004) and placebo hypoalgesia (Bingel et al., 2006; Eippert et al., 2009a; Petrovic et al., 2002). Imaging studies investigating nocebo hyperalgesia indicate that similar to placebo hypoalgesia, activation patterns involve regions such as the PAG and prefrontal cortex (Freeman et al., 2015; Kong et al., 2008; Tinnermann et al., 2017). To answer the question whether modulatory processes recruit the descending pain pathway to ultimately target spinal processing, behavioral studies have investigated spinal output such as withdrawal reflexes. These studies indicate that positive suggestions were able to reduce spinal responses (Goffaux et al., 2007; Matre et al., 2006) while unpleasant pictures were able to increase spinal responses (Roy et al., 2009). Neuroimaging studies of the spinal cord confirmed these findings by showing that pain-related spinal activity was reduced during a cognitively demanding task (Sprenger et al., 2012; Stroman et al., 2011) and during placebo hypoalgesia (Eippert et al., 2009b), which indicates that cognitive pain modulation is able to reduce nociceptive transmission at the earliest stages of the central nervous system. In contrast, spinal activity was increased during nocebo hyperalgesia, indicating elevated spinal nociceptive transmission (Geuter and Büchel, 2013; Tinnermann et al., 2017). Here, cortico-spinal imaging offers the possibility to investigate how cognitive processes modulate the crosstalk between regions of the entire descending pain system.

5. Conclusion

In this review, we have given an overview on cortico-spinal imaging with a focus on pain processing in the human central nervous system. Simultaneous imaging of interactions between the brain and spinal cord offers the possibility to reveal new aspects about the role of functional connectivity within the entire central nervous system for central pain processing. Moreover, we have sketched how several fields within the domain of clinical pain might benefit from investigating spinal responses in addition to brain responses. Although the current approaches to measure BOLD responses simultaneously in the brain and spinal cord are promising, further methodological developments will need to improve data quality and resolution and increase feasibility. Feasibility of this imaging method is especially relevant for the investigation of patient samples because the additional time that is required for a cortico-spinal neuroimaging setup might decrease patients' compliance and tolerance for fMRI experiments. This is further important in the light of the search for brain-based biomarkers for pain using fMRI (Davis et al., 2017; Mackey et al., 2019; Mouraux and Iannetti, 2018; Tracey et al., 2019), where spinal responses and interactions between the spinal cord and the brain could become an extension of biomarker research.

Apart from the various challenges related to data acquisition, the analysis of spinal data is another important and challenging issue. To further disseminate spinal fMRI applications and improve the confidence in the published results, standardized preprocessing pipelines, a

common template space for the spinal cord and reproducibility of results are necessary. Tools that have been developed to analyze spinal neuroimaging data are in rather early stages of development, as compared to brain analysis software (e.g. SPM, FSL) and validation is required. Sharing of analysis pipelines together with data would further foster the reproducibility of results, and therefore augment reliability and plausibility of spinal fMRI research. Recent initiatives from the neuroimaging community such as the Brain Imaging Data Structure (BIDS) (Gorgolewski et al., 2016), the BinderHub technology (Jupyter et al., 2018), NeuroLibre (https://www.neurolibre.com/) and the Organization for Human Brain Mapping's Aperture (https://ohbm-aperture.github.io/) will help to improve accessibility, and reproducibility of neuroimaging data analysis methods

Acknowledgments

The authors declare no conflict of interest. AT and CB are supported by the German Research Foundation, SFB936 project A06 and the BMBF and Max Planck Society. C.B is further supported by the ERC AdG 883892 - PainPersist. JCA is supported by the Canada Research Chair in Quantitative Magnetic Resonance Imaging [950-230815], the Canadian Institute of Health Research [CIHR FDN-143263], the Canada Foundation for Innovation [32454, 34824], the Natural Sciences and Engineering Research Council of Canada [RGPIN-2019-07244], the Canada First Research Excellence Fund (IVADO and TransMedTech) and the Courtois NeuroMod project. We thank Shahabeddin Vahdat, Jürgen Finsterbusch and Christine Law for kindly sharing their figures on corticospinal setups for reuse in Fig. 4. We further thank Lea Kampermann and Björn Horing for helpful comments on previous versions of the manuscript.

References

Angst, M.S., Koppert, W., Pahl, I., Clark, D.J., Schmelz, M., 2003. Short-term infusion of the μ-opioid agonist remifentanil in humans causes hyperalgesia during withdrawal. PAIN 106, 49–57. doi:10.1016/S0304-3959(03)00276-8.

Apkarian, A.V., Bushnell, M.C., Schweinhardt, P., 2013. Representation of Pain in the Brain. In: McMahon, S.B., Koltzenburg, M., Tracey, I., Turk, D. (Eds.), Wall and Melzack's Textbook of Pain. Elsevier/Saunders, Philadelphia, PA, pp. 111–128.

Apkarian, A.V., Bushnell, M.C., Treede, R.-D., Zubieta, J.-K., 2005. Human brain mechanisms of pain perception and regulation in health and disease. Eur. J. Pain 9. doi:10.1016/j.ejpain.2004.11.001, 463–463.

Atlas, L.Y., Whittington, R.A., Lindquist, M.A., Wielgosz, J., Sonty, N., Wager, T.D., 2012. Dissociable influences of opiates and expectations on pain. J. Neurosci. 32, 8053–8064. doi:10.1523/JNEUROSCI.0383-12.2012.

Baliki, M.N., Chialvo, D.R., Geha, P.Y., Levy, R.M., Harden, R.N., Parrish, T.B., Apkarian, A.V., 2006. Chronic pain and the emotional brain: Specific brain activity associated with spontaneous fluctuations of intensity of chronic back pain. J. Neurosci. 26, 12165–12173. doi:10.1523/JNEUROSCI.3576-06.2006.

Baliki, M.N., Mansour, A.R., Baria, A.T., Apkarian, A.V., 2014. Functional reorganization of the default mode network across chronic pain conditions. PLoS ONE 9, e106133. doi:10.1371/journal.pone.0106133.

Baliki, M.N., Petre, B., Torbey, S., Herrmann, K.M., Huang, L., Schnitzer, T.J., Fields, H.L., Apkarian, A.V., 2012. Corticostriatal functional connectivity predicts transition to chronic back pain. Nat. Neurosci. 15, 1117–1119. doi:10.1038/nn.3153.

Bantick, S.J., Wise, R.G., Ploghaus, A., Clare, S., Smith, S.M., Tracey, I., 2002. Imaging how attention modulates pain in humans using functional MRI. Brain 125, 310–319. doi:10.1093/brain/awf022.

Barry, R.L., Rogers, B.P., Conrad, B.N., Smith, S.A., Gore, J.C., 2016. Reproducibility of resting state spinal cord networks in healthy volunteers at 7 Tesla. NeuroImage 133, 31–40. doi:10.1016/j.neuroimage.2016.02.058.

Barry, R.L., Smith, S.A., Dula, A.N., Gore, J.C., 2014. Resting state functional connectivity in the human spinal cord. eLife 3, e02812. doi:10.7554/eLife.02812.

Barry, R.L., Vannesjo, S.J., By, S., Gore, J.C., Smith, S.A., 2018. Spinal cord MRI at 7T. NeuroImage 168, 437–451. doi:10.1016/j.neuroimage.2017.07.003.

Benedetti, F., Amanzio, M., Casadio, C., Oliaro, A., Maggi, G., 1997. Blockade of nocebo hyperalgesia by the cholecystokinin antagonist proglumide. PAIN 71, 135–140.

Benedetti, F., Amanzio, M., Vighetti, S., Asteggiano, G., 2006. The biochemical and neuroendocrine bases of the hyperalgesic nocebo effect. J. Neurosci. 26, 12014–12022. doi:10.1523/JNEUROSCI.2947-06.2006.

Bingel, U., Lorenz, J., Glauche, V., Knab, R., Gläscher, J., Weiller, C., Büchel, C., 2004. Somatotopic organization of human somatosensory cortices for pain: A single trial fMRI study. NeuroImage 23, 224–232. doi:10.1016/j.neuroimage.2004.05.021.

Bingel, U., Lorenz, J., Schoell, E., Weiller, C., Büchel, C., 2006. Mechanisms of placebo analgesia: rACC recruitment of a subcortical antinociceptive network. PAIN 120, 8–15. doi:10.1016/j.pain.2005.08.027.

Bingel, U., Wanigasekera, V., Wiech, K., Ni Mhuircheartaigh, R., Lee, M.C., Ploner, M., Tracey, I., 2011. The effect of treatment expectation on drug efficacy: Imaging the analgesic benefit of the opioid remifentanil. Sci. Transl. Med. 3, 70ra14. doi:10.1126/scitranslmed.3001244.

Blaiotta, C., Freund, P., Cardoso, M.J., Ashburner, J., 2018. Generative diffeomorphic modelling of large MRI data sets for probabilistic template construction. NeuroImage 166, 117–134. doi:10.1016/j.neuroimage.2017.10.060.

Bornhövd, K., Quante, M., Glauche, V., Bromm, B., Weiller, C., Büchel, C., 2002. Painful stimuli evoke different stimulus–response functions in the amygdala, prefrontal, insula and somatosensory cortex: A single-trial fMRI study. Brain 125, 1326–1336. doi:10.1093/brain/awf137.

Borsook, D., Becerra, L., Hargreaves, R., 2006. A role for fMRI in optimizing CNS drug development. Nat. Rev. Drug Discov. 5, 411–425. doi:10.1038/nrd2027.

Bosma, R.L., Ameli Mojarad, E., Leung, L., Pukall, C., Staud, R., Stroman, P.W., 2015. Neural correlates of temporal summation of second pain in the human brainstem and spinal cord. Hum. Brain Mapp. 5038–5050. doi:10.1002/hbm.22993.

Bosma, R.L., Mojarad, E.A., Leung, L., Pukall, C., Staud, R., Stroman, P.W., 2016. fMRI of spinal and supra-spinal correlates of temporal pain summation in fibromyalgia patients. Hum. Brain Mapp. 37, 1349–1360. doi:10.1002/hbm.23106.

Bosma, R.L., Stroman, P.W., 2015. Spinal cord response to stepwise and block presentation of thermal stimuli: A functional MRI study. J. Magn. Reson. Imaging 41, 1318–1325. doi:10.1002/jmri.24656.

Bosma, R.L., Stroman, P.W., 2014. Assessment of data acquisition parameters, and analysis techniques for noise reduction in spinal cord fMRI data. Magn. Reson. Imaging 32, 473–481. doi:10.1016/j.mri.2014.01.007.

Bouwense, S.A.W., Olesen, S.S., Drewes, A.M., Frøkjær, J.B., Goor, H.van, Wilder-Smith, O.H.G., 2013. Is altered central pain processing related to disease stage in chronic pancreatitis patients with pain? An exploratory study. PLOS ONE 8, e55460. doi:10.1371/journal.pone.0055460.

Bouwman, C.J.C., Wilmink, J.T., Mess, W.H., Backes, W.H., 2008. Spinal cord functional MRI at 3 T: Gradient echo echo-planar imaging versus turbo spin echo. NeuroImage 43, 288–296. doi:10.1016/j.neuroimage.2008.07.024.

Branthwaite, A., Cooper, P., 1981. Analgesic effects of branding in treatment of headaches. Br. Med. J. Clin. Res. Ed. 282, 1576–1578.

Brodersen, K.H., Wiech, K., Lomakina, E.I., Lin, C., Buhmann, J.M., Bingel, U., Ploner, M., Stephan, K.E., Tracey, I., 2012. Decoding the perception of pain from fMRI using multivariate pattern analysis. NeuroImage 63, 1162–1170. doi:10.1016/j.neuroimage.2012.08.035.

Brooks, J.C.W., 2014. Chapter 4.2 - physiological noise modeling and analysis for spinal cord fMRI. In: Cohen-Adad, J., Wheeler-Kingshott, C.A.M. (Eds.), Quantitative MRI of the Spinal Cord. Academic Press, San Diego, pp. 240–257. doi:10.1016/B978-0-12-396973-6.00016-2.

Brooks, J.C.W., Beckmann, C.F., Miller, K.L., Wise, R.G., Porro, C.A., Tracey, I., Jenkinson, M., 2008. Physiological noise modelling for spinal functional magnetic resonance imaging studies. NeuroImage 39, 680–692. doi:10.1016/j.neuroimage.2007.09.018.

Brooks, J.C.W., Kong, Y., Lee, M.C., Warnaby, C.E., Wanigasekera, V., Jenkinson, M., Tracey, I., 2012. Stimulus site and modality dependence of functional activity within the human spinal cord. J. Neurosci. 32, 6231–6239. doi:10.1523/JNEUROSCI.2543-11.2012.

Brooks, J.C.W., Zambreanu, L., Godinez, A., Craig, A.D., (Bud), Tracey, I., 2005. Somatotopic organisation of the human insula to painful heat studied with high resolution functional imaging. NeuroImage 27, 201–209. doi:10.1016/j.neuroimage.2005.03.041.

Buhle, J.T., Stevens, B.L., Friedman, J.J., Wager, T.D., 2012. Distraction and placebo: Two separate routes to pain control. Psychol. Sci. 23, 246–253. doi:10.1177/0956797611427919.

Bushnell, M.C., Čeko, M., Low, L.A., 2013. Cognitive and emotional control of pain and its disruption in chronic pain. Nat. Rev. Neurosci. 14, 502–511. doi:10.1038/nrn3516.

Cadotte, D.W., Cadotte, A., Cohen-Adad, J., Fleet, D., Livne, M., Wilson, J.R., Mikulis, D., Nugaeva, N., Fehlings, M.G., 2015. Characterizing the location of spinal and vertebral levels in the human cervical spinal cord. Am. J. Neuroradiol. 36, 803–810. doi:10.3174/ajnr.A4192.

Cahill, C.M., Stroman, P.W., 2011. Mapping of neural activity produced by thermal pain in the healthy human spinal cord and brain stem: A functional magnetic resonance imaging study. Magn. Reson. Imaging 29, 342–352. doi:10.1016/j.mri.2010.10.007.

Carmichael, O., Schwarz, A.J., Chatham, C.H., Scott, D., Turner, J.A., Upadhyay, J., Coimbra, A., Goodman, J.A., Baumgartner, R., English, B.A., Apolzan, J.W., Shankapal, P., Hawkins, K.R., 2018. The role of fMRI in drug development. Drug Discov. Today 23, 333–348. doi:10.1016/j.drudis.2017.11.012.

Chen, T., Taniguchi, W., Chen, Q.-Y., Tozaki-Saitoh, H., Song, Q., Liu, R.-H., Koga, K., Matsuda, T., Kaito-Sugimura, Y., Wang, J., Li, Z.-H., Lu, Y.-C., Inoue, K., Tsuda, M., Li, Y.-Q., Nakatsuka, T., Zhuo, M., 2018. Top-down descending facilitation of spinal sensory excitatory transmission from the anterior cingulate cortex. Nat. Commun. 9, 1886. doi:10.1038/s41467-018-04309-2.

Coghill, R.C., Sang, C.N., Maisog, J.M., Iadarola, M.J., 1999. Pain intensity processing within the human brain: a bilateral, distributed mechanism. J. Neurophysiol. 82, 1934–1943.

Cohen-Adad, J., 2017. Functional magnetic resonance imaging of the spinal cord: Current status and future developments. Semin. Ultrasound CT MRI, Spinal Cord Imaging 38 (Part 2), 176–186. doi:10.1053/j.sult.2016.07.007.

Cohen-Adad, J., 2020. https://github.com/spine-generic/protocols.

Cohen-Adad, J., Gauthier, C.J., Brooks, J.C.W., Slessarev, M., Han, J., Fisher, J.A., Rossig-

nol, S., Hoge, R.D., 2010. BOLD signal responses to controlled hypercapnia in human spinal cord. NeuroImage 50, 1074–1084. doi:10.1016/j.neuroimage.2009.12.122.

Cohen-Adad, J., Wald, L.L., 2014. Chapter 2.1 - Array Coils. In: Cohen-Adad, J., Wheeler-Kingshott, C.A.M. (Eds.), Quantitative MRI of the Spinal Cord. Academic Press, San Diego, pp. 59–67. doi:10.1016/B978-0-12-396973-6.00005-8.

Cook, D.B., Lange, G., Ciccone, D.S., Liu, W.-C., Steffener, J., Natelson, B.H., 2004. Functional imaging of pain in patients with primary fibromyalgia. J. Rheumatol. 31, 364–378.

Corder, G., Castro, D.C., Bruchas, M.R., Scherrer, G., 2018. Endogenous and exogenous opioids in pain. Annu. Rev. Neurosci. 41, 453–473. doi:10.1146/annurev-neuro-080317-061522.

David, G., Mohammadi, S., Martin, A.R., Cohen-Adad, J., Weiskopf, N., Thompson, A., Freund, P., 2019. Traumatic and nontraumatic spinal cord injury: Pathological insights from neuroimaging. Nat. Rev. Neurol. 15, 718–731. doi:10.1038/s41582-019-0270-5.

Davis, K.D., Bushnell, M.C., Iannetti, G.D., St. Lawrence, K., Coghill, R., 2015. Evidence against pain specificity in the dorsal posterior insula. F1000Research doi:10.12688/f1000research.6833.1.

Davis, K.D., Flor, H., Greely, H.T., Iannetti, G.D., Mackey, S., Ploner, M., Pustilnik, A., Tracey, I., Treede, R.-D., Wager, T.D., 2017. Brain imaging tests for chronic pain: Medical, legal and ethical issues and recommendations. Nat. Rev. Neurol. 13, 624–638. doi:10.1038/nrneurol.2017.122.

De Leener, B., Lévy, S., Dupont, S.M., Fonov, V.S., Stikov, N., Louis Collins, D., Callot, V., Cohen-Adad, J., 2017. SCT: Spinal Cord Toolbox, an open-source software for processing spinal cord MRI data. NeuroImage 145, 24–43. doi:10.1016/j.neuroimage.2016.10.009.

Deckers, R.H.R., van Gelderen, P., Ries, M., Barret, O., Duyn, J.H., Ikonomidou, V.N., Fukunaga, M., Glover, G.H., de Zwart, J.A., 2006. An adaptive filter for suppression of cardiac and respiratory noise in MRI time-series data. NeuroImage 33, 1072–1081. doi:10.1016/j.neuroimage.2006.08.006.

Dobek, C.E., Beynon, M.E., Bosma, R.L., Stroman, P.W., 2014. Music modulation of pain perception and pain-related activity in the brain, brain stem, and spinal cord: A functional magnetic resonance imaging study. J. Pain 15, 1057–1068. doi:10.1016/j.jpain.2014.07.006.

Dostrovsky, J.O., Craig, A.D., 2013. Ascending projection systems. In: McMahon, S.B., Koltzenburg, M., Tracey, I., Turk, D. (Eds.), Wall and Melzack's Textbook of Pain. Elsevier/Saunders, Philadelphia, PA, pp. 182–197.

Duerden, E.G., Albanese, M.-C., 2013. Localization of pain-related brain activation: A meta-analysis of neuroimaging data. Hum. Brain Mapp. 34, 109–149. doi:10.1002/hbm.21416.

Duff, E.P., Vennart, W., Wise, R.G., Howard, M.A., Harris, R.E., Lee, M., Wartolowska, K., Wanigasekera, V., Wilson, F.J., Whitlock, M., Tracey, I., Woolrich, M.W., Smith, S.M., 2015. Learning to identify CNS drug action and efficacy using multistudy fMRI data. Sci. Transl. Med. 7, 274ra16. doi:10.1126/scitranslmed.3008438.

Duval, T., McNab, J.A., Setsompop, K., Witzel, T., Schneider, T., Huang, S.Y., Keil, B., Klawiter, E.C., Wald, L.L., Cohen-Adad, J., 2015. In vivo mapping of human spinal cord microstructure at 300mT/m. NeuroImage 118, 494–507. doi:10.1016/j.neuroimage.2015.06.038.

Eippert, F., Bingel, U., Schoell, E.D., Yacubian, J., Klinger, R., Lorenz, J., Büchel, C., 2009a. Activation of the opioidergic descending pain control system underlies placebo analgesia. Neuron 63, 533–543. doi:10.1016/j.neuron.2009.07.014.

Eippert, F., Finsterbusch, J., Bingel, U., Büchel, C., 2009b. Direct evidence for spinal cord involvement in placebo analgesia. Science 326, 404.

Eippert, F., Kong, Y., Jenkinson, M., Tracey, I., Brooks, J.C.W., 2017a. Denoising spinal cord fMRI data: approaches to acquisition and analysis. NeuroImage 154, 255–266. doi:10.1016/j.neuroimage.2016.09.065.

Eippert, F., Kong, Y., Winkler, A.M., Andersson, J.L., Finsterbusch, J., Büchel, C., Brooks, J.C.W., Tracey, I., 2017b. Investigating resting-state functional connectivity in the cervical spinal cord at 3T. NeuroImage 147, 589–601. doi:10.1016/j.neuroimage.2016.12.072.

Eryaman, Y., Guerin, B., Keil, B., Mareyam, A., Herraiz, J.L., Kosior, R.K., Martin, A., Torrado-Carvajal, A., Malpica, N., Hernandez-Tamames, J.A., Schiavi, E., Adalsteinsson, E., Wald, L.L., 2015. SAR Reduction in 7T C-Spine Imaging Using a "Dark Modes" Transmit Array Strategy. Magn. Reson. Med. 73, 1533–1539. doi:10.1002/mrm.25246.

Favilla, S., Huber, A., Pagnoni, G., Lui, F., Facchin, P., Cocchi, M., Baraldi, P., Porro, C.A., 2014. Ranking brain areas encoding the perceived level of pain from fMRI data. NeuroImage 90, 153–162. doi:10.1016/j.neuroimage.2014.01.001.

Fehse, K., Maikowski, L., Simmank, F., Gutyrchik, E., Meissner, K., 2015. Placebo responses to original vs generic ASA brands during exposure to noxious heat: A pilot fMRI study of neurofunctional correlates. Pain Med. 16, 1967–1974. doi:10.1111/pme.12783.

Fields, H., 2004. State-dependent opioid control of pain. Nat. Rev. Neurosci. 5, 565–575. doi:10.1038/nrn1431.

Finsterbusch, J., 2014. Chapter 2.2 - B0 Inhomogeneity and Shimming. In: Cohen-Adad, J., Wheeler-Kingshott, C.A.M. (Eds.), Quantitative MRI of the Spinal Cord. Academic Press, San Diego, pp. 68–90. doi:10.1016/B978-0-12-396973-6.00006-X.

Finsterbusch, J., Eippert, F., Büchel, C., 2012. Single, slice-specific z-shim gradient pulses improve T2*-weighted imaging of the spinal cord. NeuroImage 59, 2307–2315. doi:10.1016/j.neuroimage.2011.09.038.

Finsterbusch, J., Sprenger, C., Büchel, C., 2013. Combined T2*-weighted measurements of the human brain and cervical spinal cord with a dynamic shim update. NeuroImage 79, 153–161. doi:10.1016/j.neuroimage.2013.04.021.

Fonov, V., Evans, A.C., Botteron, K., Almli, C.R., McKinstry, R.C., Collins, D.L., 2011. Unbiased average age-appropriate atlases for pediatric studies. NeuroImage 54, 313–327. doi:10.1016/j.neuroimage.2010.07.033.

Fonov, V.S., Le Troter, A., Taso, M., De Leener, B., Lévêque, G., Benhamou, M., Sdika, M., Benali, H., Pradat, P.-F., Collins, D.L., Callot, V., Cohen-Adad, J., 2014. Framework for integrated MRI average of the spinal cord white and gray matter: The MNI–Poly–AMU template. NeuroImage 102, 817–827. doi:10.1016/j.neuroimage.2014.08.057.

Freeman, S., Yu, R., Egorova, N., Chen, X., Kirsch, I., Claggett, B., Kaptchuk, T.J., Gollub, R.L., Kong, J., 2015. Distinct neural representations of placebo and nocebo effects. NeuroImage 112, 197–207. doi:10.1016/j.neuroimage.2015.03.015.

Gelderen, P.van, Zwart, J.A.de, Starewicz, P., Hinks, R.S., Duyn, J.H., 2007. Real-time shimming to compensate for respiration-induced B0 fluctuations. Magn. Reson. Med. 57, 362–368. doi:10.1002/mrm.21136.

Geuter, S., Büchel, C., 2013. Facilitation of pain in the human spinal cord by nocebo treatment. J. Neurosci. 33, 13784–13790. doi:10.1523/JNEUROSCI.2191-13.2013.

Geuter, S., Eippert, F., Hindi Attar, C., Büchel, C., 2013. Cortical and subcortical responses to high and low effective placebo treatments. NeuroImage 67, 227–236. doi:10.1016/j.neuroimage.2012.11.029.

Geuter, S., Koban, L., Wager, T.D., 2017. The cognitive neuroscience of placebo effects: concepts, predictions, and physiology. Annu. Rev. Neurosci. 40. doi:10.1146/annurev-neuro-072116-031132, null.

Ghazni, N.F., Cahill, C.M., Stroman, P.W., 2010. Tactile sensory and pain networks in the human spinal cord and brain stem mapped by means of functional MR imaging. Am. J. Neuroradiol. 31, 661–667. doi:10.3174/ajnr.A1909.

Giesecke, T., Gracely, R.H., Grant, M.A.B., Nachemson, A., Petzke, F., Williams, D.A., Clauw, D.J., 2004. Evidence of augmented central pain processing in idiopathic chronic low back pain. Arthritis Rheum 50, 613–623. doi:10.1002/art.20063.

Glover, G.H., Li, T.-Q., Ress, D. , 2000. Image-based method for retrospective correction of physiological motion effects in fMRI: RETROICOR. Magn. Reson. Med. 44, 162–167.

Goffaux, P., Redmond, W.J., Rainville, P., Marchand, S., 2007. Descending analgesia – When the spine echoes what the brain expects. PAIN 130, 137–143. doi:10.1016/j.pain.2006.11.011.

Gorgolewski, K.J., Auer, T., Calhoun, V.D., Craddock, R.C., Das, S., Duff, E.P., Flandin, G., Ghosh, S.S., Glatard, T., Halchenko, Y.O., Handwerker, D.A., Hanke, M., Keator, D., Li, X., Michael, Z., Maumet, C., Nichols, B.N., Nichols, T.E., Pellman, J., Poline, J.-B., Rokem, A., Schaefer, G., Sochat, V., Triplett, W., Turner, J.A., Varoquaux, G., Poldrack, R.A., 2016. The brain imaging data structure, a format for organizing and describing outputs of neuroimaging experiments. Sci. Data 3, 1–9. doi:10.1038/sdata.2016.44.

Grussu, F., Schneider, T., Zhang, H., Alexander, D.C., Wheeler–Kingshott, C.A.M., 2015. Neurite orientation dispersion and density imaging of the healthy cervical spinal cord in vivo. NeuroImage 111, 590–601. doi:10.1016/j.neuroimage.2015.01.045.

Guy, A.W., 1971. Analyses of electromagnetic fields induced in biological tissues by thermographic studies on equivalent phantom models. IEEE Trans. Microw. Theory Tech. 19, 205–214. doi:10.1109/TMTT.1968.1127484.

Gwilym, S.E., Keltner, J.R., Warnaby, C.E., Carr, A.J., Chizh, B., Chessell, I., Tracey, I., 2009. Psychophysical and functional imaging evidence supporting the presence of central sensitization in a cohort of osteoarthritis patients. Arthritis Care Res 61, 1226–1234. doi:10.1002/art.24837.

Hansen, T.M., Olesen, A.E., Graversen, C., Drewes, A.M., Frøkjær, J.B., 2015. The effect of oral morphine on pain-related brain activation – An experimental functional magnetic resonance imaging study. Basic Clin. Pharmacol. Toxicol. 117, 316–322. doi:10.1111/bcpt.12415.

Hashmi, J.A., Baliki, M.N., Huang, L., Baria, A.T., Torbey, S., Hermann, K.M., Schnitzer, T.J., Apkarian, A.V., 2013. Shape shifting pain: chronification of back pain shifts brain representation from nociceptive to emotional circuits. Brain 136, 2751–2768. doi:10.1093/brain/awt211.

Heilbronner, S.R., Hayden, B.Y., 2016. Dorsal anterior cingulate cortex: a bottom-up view. Annu. Rev. Neurosci. 39, 149. doi:10.1146/annurev-neuro-070815-013952.

Heinricher, M.M., Fields, H.L., 2013. Central nervous system mechanisms of pain modulation. In: McMahon, S.B., Koltzenburg, M., Tracey, I., Turk, D. (Eds.), Wall and Melzack's Textbook of Pain. Elsevier/Saunders, Philadelphia, PA, pp. 129–142.

Heinricher, M.M., Tavares, I., Leith, J.L., Lumb, B.M., 2009. Descending control of nociception: Specificity, recruitment and plasticity. Brain Res. Rev. 60, 214–225. doi:10.1016/j.brainresrev.2008.12.009.

Hemington, K.S., Wu, Q., Kucyi, A., Inman, R.D., Davis, K.D., 2016. Abnormal cross-network functional connectivity in chronic pain and its association with clinical symptoms. Brain Struct. Funct. 221, 4203–4219. doi:10.1007/s00429-015-1161-1.

Henning, A., Koning, W., Fuchs, A., Raaijmakers, A., Bluemink, J.J., Berg, C.A.T., van den, Boer, V.O., Klomp, D.W.J., 2016. 1H MRS in the human spinal cord at 7 T using a dielectric waveguide transmitter, RF shimming and a high density receive array. NMR Biomed. 29, 1231–1239. doi:10.1002/nbm.3541.

Hetherington, H.P., Chu, W.-J., Gonen, O., Pan, J.W., 2006. Robust fully automated shimming of the human brain for high-field 1H spectroscopic imaging. Magn. Reson. Med. 56, 26–33. doi:10.1002/mrm.20941.

Horing, B., Sprenger, C., Büchel, C., 2019. The parietal operculum preferentially encodes heat pain and not salience. PLOS Biol 17, e3000205. doi:10.1371/journal.pbio.3000205.

Hsieh, J.-C., Belfrage, M., Stone-Elander, S., Hansson, P., Ingvar, M., 1995. Central representation of chronic ongoing neuropathic pain studied by positron emission tomography. PAIN 63, 225–236. doi:10.1016/0304-3959(95)00048-W.

Iannetti, G.D., Mouraux, A., 2010. From the neuromatrix to the pain matrix (and back). Exp. Brain Res. 205, 1–12. doi:10.1007/s00221-010-2340-1.

Iannetti, G.D., Zambreanu, L., Wise, R.G., Buchanan, T.J., Huggins, J.P., Smart, T.S., Vennart, W., Tracey, I., 2005. Pharmacological modulation of pain-related brain activity during normal and central sensitization states in humans. Proc. Natl. Acad. Sci. 102, 18195–18200. doi:10.1073/pnas.0506624102.

Iglesias, C., Sangari, S., Mendili, M.-M.E., Benali, H., Marchand-Pauvert, V., Pradat, P.-F., 2015. Electrophysiological and spinal imaging evidences for sen-

sory dysfunction in amyotrophic lateral sclerosis. BMJ Open 5, e007659. doi:10.1136/bmjopen-2015-007659.

Ioachim, G., Powers, J.M., Stroman, P.W., 2019. Comparing coordinated networks across the brainstem and spinal cord in the resting state and altered cognitive state. Brain Connect 9, 415–424. doi:10.1089/brain.2018.0659.

Islam, H., Law, C.S.W., Weber, K.A., Mackey, S.C., Glover, G.H., 2019. Dynamic per slice shimming for simultaneous brain and spinal cord fMRI. Magn. Reson. Med. 81, 825–838. doi:10.1002/mrm.27388.

Jarrett, M.E., Shulman, R.J., Cain, K.C., Deechakawan, W., Smith, L.T., Richebé, P., Eugenio, M., Heitkemper, M.M., 2014. Conditioned pain modulation in women with irritable bowel syndrome. Biol. Res. Nurs. 16, 368–377. doi:10.1177/1099800413520486.

Jensen, K.B., Loitoile, R., Kosek, E., Petzke, F., Carville, S., Fransson, P., Marcus, H., Williams, S.C., Choy, E., Mainguy, Y., Vitton, O., Gracely, R.H., Gollub, R., Ingvar, M., Kong, J., 2012. Patients with fibromyalgia display less functional connectivity in the brain's pain inhibitory network. Mol. Pain 8, 32. doi:10.1186/1744-8069-8-32.

Jochimsen, T.H., Norris, D.G., Möller, H.E., 2005. Is there a change in water proton density associated with functional magnetic resonance imaging? Magn. Reson. Med. 53, 470–473. doi:10.1002/mrm.20351.

Jupyter, P., Bussonnier, M., Forde, J., Freeman, J., Granger, B., Head, T., Holdgraf, C., Kelley, K., Nalvarte, G., Osheroff, A., Pacer, M., Panda, Y., Perez, F., Ragan-Kelley, B., Willing, C., 2018. Binder 2.0 - Reproducible, interactive, sharable environments for science at scale. In: Presented at the Python in Science Conference, Austin, Texas, pp. 113–120. doi:10.25080/Majora-4af1f417-011.

Khan, H.S., Stroman, P.W., 2015. Inter-individual differences in pain processing investigated by functional magnetic resonance imaging of the brainstem and spinal cord. Neuroscience 307, 231–241. doi:10.1016/j.neuroscience.2015.08.059.

Kim, J.H., Lee, C.W., Chun, K.S., Shin, W.H., Bae, H.-G., Chang, J.C., 2012. Morphometric relationship between the cervicothoracic cord segments and vertebral bodies. J. Korean Neurosurg. Soc. 52, 384–390. doi:10.3340/jkns.2012.52.4.384.

Kinany, N., Pirondini, E., Martuzzi, R., Mattera, L., Micera, S., Van de Ville, D., 2019. Functional imaging of rostrocaudal spinal activity during upper limb motor tasks. NeuroImage 200, 590–600. doi:10.1016/j.neuroimage.2019.05.036.

Kong, J., Gollub, R.L., Polich, G., Kirsch, I., LaViolette, P., Vangel, M., Rosen, B., Kaptchuk, T.J., 2008. A functional magnetic resonance imaging study on the neural mechanisms of hyperalgesic nocebo effect. J. Neurosci. 28, 13354–13362. doi:10.1523/JNEUROSCI.2944-08.2008.

Kong, J., Kaptchuk, T.J., Polich, G., Kirsch, I., Vangel, M., Zyloney, C., Rosen, B., Gollub, R.L., 2009. An fMRI study on the interaction and dissociation between expectation of pain relief and acupuncture treatment. NeuroImage 47, 1066–1076. doi:10.1016/j.neuroimage.2009.05.087.

Kong, J., Tu, P., Zyloney, C., Su, T., 2010. Intrinsic functional connectivity of the periaqueductal gray, a resting fMRI study. Behav. Brain Res. 211, 215–219. doi:10.1016/j.bbr.2010.03.042.

Kong, Y., Eippert, F., Beckmann, C.F., Andersson, J., Finsterbusch, J., Büchel, C., Tracey, I., Brooks, J.C.W., 2014. Intrinsically organized resting state networks in the human spinal cord. Proc. Natl. Acad. Sci. 111, 18067–18072. doi:10.1073/pnas.1414293111.

Kong, Y., Jenkinson, M., Andersson, J., Tracey, I., Brooks, J.C.W., 2012. Assessment of physiological noise modelling methods for functional imaging of the spinal cord. NeuroImage 60, 1538–1549. doi:10.1016/j.neuroimage.2011.11.077.

Kraff, O., Bitz, A.K., Kruszona, S., Orzada, S., Schaefer, L.C., Theysohn, J.M., Maderwald, S., Ladd, M.E., Quick, H.H., 2009. An eight-channel phased array RF coil for spine MR imaging at 7 T. Invest. Radiol. 44, 734–740. doi:10.1097/RLI.0b013e3181b24ab7.

Kucyi, A., Davis, K.D., 2015. The dynamic pain connectome. Trends Neurosci 38, 86–95. doi:10.1016/j.tins.2014.11.006.

Kucyi, A., Moayedi, M., Weissman-Fogel, I., Goldberg, M.B., Freeman, B.V., Tenenbaum, H.C., Davis, K.D., 2014. Enhanced medial prefrontal-default mode network functional connectivity in chronic pain and its association with pain rumination. J. Neurosci. 34, 3969–3975. doi:10.1523/JNEUROSCI.5055-. 13.2014.

Kuner, R., 2010. Central mechanisms of pathological pain. Nat. Med. 16, 1258–1266. doi:10.1038/nm.2231.

Kutch, J.J., Labus, J.S., Harris, R.E., Martucci, K.T., Farmer, M.A., Fenske, S., Fling, C., Ichesco, E., Peltier, S., Petre, B., Guo, W., Hou, X., Stephens, A.J., Mullins, C., Clauw, D.J., Mackey, S.C., Apkarian, A.V., Landis, J.R., Mayer, E.A., 2017. Resting-state functional connectivity predicts longitudinal pain symptom change in urologic chronic pelvic pain syndrome: A MAPP Network Study. Pain 158, 1069–1082. doi:10.1097/j.pain.0000000000000886.

Lee, M.w.l., McPhee, R.w., Stringer, M.d., 2008. An evidence-based approach to human dermatomes. Clin. Anat. 21, 363–373. doi:10.1002/ca.20636.

Lee, M.C., Ploner, M., Wiech, K., Bingel, U., Wanigasekera, V., Brooks, J., Menon, D.K., Tracey, I., 2013. Amygdala activity contributes to the dissociative effect of cannabis on pain perception. PAIN 154, 124–134. doi:10.1016/j.pain.2012.09.017.

Legrain, V., Iannetti, G.D., Plaghki, L., Mouraux, A., 2011. The pain matrix reloaded: A salience detection system for the body. Prog. Neurobiol. 93, 111–124. doi:10.1016/j.pneurobio.2010.10.005.

Lévy, S., Benhamou, M., Naaman, C., Rainville, P., Callot, V., Cohen-Adad, J., 2015. White matter atlas of the human spinal cord with estimation of partial volume effect. NeuroImage 119, 262–271. doi:10.1016/j.neuroimage.2015.06.040.

Li, Z., Liu, M., Lan, L., Zeng, F., Makris, N., Liang, Y., Guo, T., Wu, F., Gao, Y., Dong, M., Yang, J., Li, Y., Gong, Q., Liang, F., Kong, J., 2016. Altered periaqueductal gray resting state functional connectivity in migraine and the modulation effect of treatment. Sci. Rep. 6, 1–11. doi:10.1038/srep20298.

Liang, M., Mouraux, A., Iannetti, G.D., 2011. Parallel processing of nociceptive and non-nociceptive somatosensory information in the human primary and secondary somatosensory cortices: Evidence from dynamic causal modeling of functional magnetic resonance imaging data. J. Neurosci. 31, 8976–8985. doi:10.1523/JNEUROSCI.6207-10.2011.

Lindquist, M.A., Krishnan, A., López-Solà, M., Jepma, M., Woo, C.-W., Koban, L., Roy, M., Atlas, L.Y., Schmidt, L., Chang, L.J., Reynolds Losin, E.A., Eisenbarth, H., Ashar, Y.K., Delk, E., Wager, T.D., 2017. Group-regularized individual prediction: Theory and application to pain. NeuroImage 145, 274–287. doi:10.1016/j.neuroimage.2015.10.074.

Loggia, M.L., Kim, J., Gollub, R.L., Vangel, M.G., Kirsch, I., Kong, J., Wasan, A.D., Napadow, V., 2013. Default mode network connectivity encodes clinical pain: An arterial spin labeling study. PAIN 154, 24–33. doi:10.1016/j.pain.2012.07.029.

López-Solà, M., Woo, C.-W., Pujol, J., Deus, J., Harrison, B.J., Monfort, J., Wager, T.D., 2017. Towards a neurophysiological signature for fibromyalgia. PAIN 158, 34–47. doi:10.1097/j.pain.0000000000000707.

Mackey, S., Greely, H.T., Martucci, K.T., 2019. Neuroimaging-based pain biomarkers: definitions, clinical and research applications, and evaluation frameworks to achieve personalized pain medicine. Pain Rep 4, e762. doi:10.1097/PR9.0000000000000762.

Mainero, C., Boshyan, J., Hadjikhani, N., 2011. Altered functional magnetic resonance imaging resting-state connectivity in periaqueductal gray networks in migraine. Ann. Neurol. 70, 838–845. doi:10.1002/ana.22537.

Mancini, F., Haggard, P., Iannetti, G.D., Longo, M.R., Sereno, M.I., 2012. Fine-grained nociceptive maps in primary somatosensory cortex. J. Neurosci. 32, 17155–17162. doi:10.1523/JNEUROSCI.3059-12.2012.

Mano, H., Kotecha, G., Leibnitz, K., Matsubara, T., Sprenger, C., Nakae, A., Shenker, N., Shibata, M., Voon, V., Yoshida, W., Lee, M., Yanagida, T., Kawato, M., Rosa, M.J., Seymour, B., 2018. Classification and characterisation of brain network changes in chronic back pain: A multicenter study. Wellcome Open Res. 3, 19. doi:10.12688/wellcomeopenres.14069.2.

Mansour, A., Baria, A.T., Tetreault, P., Vachon-Presseau, E., Chang, P.-C., Huang, L., Apkarian, A.V., Baliki, M.N., 2016. Global disruption of degree rank order: A hallmark of chronic pain. Sci. Rep. 6, 1–17. doi:10.1038/srep34853.

Martucci, K.T., Weber, K.A., Mackey, S.C., 2019. Altered cervical spinal cord resting-state activity in fibromyalgia. Arthritis Rheumatol 71, 441–450. doi:10.1002/art.40746.

Matre, D., Casey, K.L., Knardahl, S., 2006. Placebo-induced changes in spinal cord pain processing. J. Neurosci. 26, 559–563. doi:10.1523/JNEUROSCI.4218-05.2006.

Mazzola, L., Isnard, J., Mauguière, F., 2006. Somatosensory and pain responses to stimulation of the second somatosensory area (SII) in humans. A comparison with SI and insular responses. Cereb. Cortex 16, 960–968. doi:10.1093/cercor/bhj038.

Mazzola, L., Isnard, J., Peyron, R., Guénot, M., Mauguière, F., 2009. Somatotopic organization of pain responses to direct electrical stimulation of the human insular cortex. PAIN 146, 99–104. doi:10.1016/j.pain.2009.07.014.

McIver, T.A., Kornelsen, J., Stroman, P.W., 2018. Functional MRI reveals emotional modulation of pain processing in the human cervical spinal cord and brainstem. J. Phys. Med 1. doi:10.36959/942/335.

Melzack, R., 1999. From the gate to the neuromatrix. PAIN 82, 121–126. doi:10.1016/S0304-3959(99)00145-1.

Melzack, R., Casey, K.L., 1968. Sensory, motivational and central control determinants of pain: A new conceptual model. In: Kenshalo, D.R. (Ed.), International Symposium on the Skin Senses. C.C. Thomas, Springfield, pp. 423–435.

Melzack, R., Wall, P.D., 1965. Pain mechanisms: A new theory. Science 150, 971–979. doi:10.1126/science.150.3699.971.

Moffitt, M.A., Dale, B.M., Duerk, J.L., Grill, W.M., 2005. Functional magnetic resonance imaging of the human lumbar spinal cord. J. Magn. Reson. Imaging 21, 527–535. doi:10.1002/jmri.20314.

Mohammadi, S., Freund, P., Feiweier, T., Curt, A., Weiskopf, N., 2013. The impact of post-processing on spinal cord diffusion tensor imaging. NeuroImage 70, 377–385. doi:10.1016/j.neuroimage.2012.12.058.

Montgomery, G.H., Kirsch, I., 1997. Classical conditioning and the placebo effect. PAIN 72, 107–113.

Morgan, V., Pickens, D., Gautam, S., Kessler, R., Mertz, H., 2005. Amitriptyline reduces rectal pain related activation of the anterior cingulate cortex in patients with irritable bowel syndrome. Gut 54, 601–607. doi:10.1136/gut.2004.047423.

Mouraux, A., Diukova, A., Lee, M.C., Wise, R.G., Iannetti, G.D., 2011. A multisensory investigation of the functional significance of the "pain matrix.". NeuroImage 54, 2237–2249. doi:10.1016/j.neuroimage.2010.09.084.

Mouraux, A., Iannetti, G.D., 2018. The search for pain biomarkers in the human brain. Brain 141, 3290–3307. doi:10.1093/brain/awy281.

Napadow, V., LaCount, L., Park, K., As-Sanie, S., Clauw, D.J., Harris, R.E., 2010. Intrinsic brain connectivity in fibromyalgia is associated with chronic pain intensity. Arthritis Rheum 62, 2545–2555. doi:10.1002/art.27497.

Nash, P., Wiley, K., Brown, J., Shinaman, R., Ludlow, D., Sawyer, A.-M., Glover, G., Mackey, S., 2013. Functional magnetic resonance imaging identifies somatotopic organization of nociception in the human spinal cord. PAIN 154, 776–781. doi:10.1016/j.pain.2012.11.008.

Oertel, B.G., Lötsch, J., 2013. Clinical pharmacology of analgesics assessed with human experimental pain models: bridging basic and clinical research. Br. J. Pharmacol. 168, 534–553. doi:10.1111/bph.12023.

Oertel, B.G., Preibisch, C., Wallenhorst, T., Hummel, T., Geisslinger, G., Lanfermann, H., Lötsch, J., 2008. Differential opioid action on sensory and affective cerebral pain processing. Clin. Pharmacol. Ther. 83, 577–588. doi:10.1038/sj.clpt.6100441.

Paquin, M.-Ê., Mendili, M.M.E., Gros, C., Dupont, S.M., Cohen-Adad, J., Pradat, P.-F., 2017. Spinal cord gray matter atrophy in amyotrophic lateral sclerosis. Am. J. Neuroradiol. doi:10.3174/ajnr.A5427.

Parker, D.B., Razlighi, Q.R., 2019. The benefit of slice timing correction in common fMRI preprocessing pipelines. Front. Neurosci. 13. doi:10.3389/fnins.2019.00821.

Peciña, M., Azhar, H., Love, T.M., Lu, T., Fredrickson, B.L., Stohler, C.S., Zubieta, J.-K.,

2012. Personality trait predictors of placebo analgesia and neurobiological correlates. Neuropsychopharmacology 38, 639–646. doi:10.1038/npp.2012.227.

Penfield, W., Boldrey, E., 1937. Somatic motor and sensory representation in the cerebral cortex of man as studied by electrical stimulation. Brain J. Neurol. 60, 389–443. doi:10.1093/brain/60.4.389.

Perone, C.S., Calabrese, E., Cohen-Adad, J., 2018. Spinal cord gray matter segmentation using deep dilated convolutions. Sci. Rep. 8, 1–13. doi:10.1038/s41598-018-24304-3.

Petrovic, P., Kalso, E., Petersson, K.M., Ingvar, M., 2002. Placebo and opioid analgesia – Imaging a shared neuronal network. Science 295, 1737–1740. doi:10.1126/science.1067176.

Piché, M., Cohen-Adad, J., Nejad, M.K., Perlbarg, V., Xie, G., Beaudoin, G., Benali, H., Rainville, P., 2009. Characterization of cardiac-related noise in fMRI of the cervical spinal cord. Magn. Reson. Imaging 27, 300–310. doi:10.1016/j.mri.2008.07.019.

Piché, M., Paquette, T., Leblond, H., 2017. Tight neurovascular coupling in the spinal cord during nociceptive stimulation in intact and spinal rats. Neuroscience 355, 1–8. doi:10.1016/j.neuroscience.2017.04.038.

Ploner, M., Lee, M.C., Wiech, K., Bingel, U., Tracey, I., 2010. Prestimulus functional connectivity determines pain perception in humans. Proc. Natl. Acad. Sci. 107, 355–360. doi:10.1073/pnas.0906186106.

Power, J.D., Plitt, M., Kundu, P., Bandettini, P.A., Martin, A., 2017. Temporal interpolation alters motion in fMRI scans: Magnitudes and consequences for artifact detection. PLOS ONE 12, e0182939. doi:10.1371/journal.pone.0182939.

Rempe, T., Wolff, S., Riedel, C., Baron, R., Stroman, P.W., Jansen, O., Gierthmühlen, J., 2015. Spinal and supraspinal processing of thermal stimuli: An fMRI study. J. Magn. Reson. Imaging 41, 1046–1055. doi:10.1002/jmri.24627.

Rempe, T., Wolff, S., Riedel, C., Baron, R., Stroman, P.W., Jansen, O., Gierthmühlen, J., 2014. Spinal fMRI reveals decreased descending inhibition during secondary mechanical hyperalgesia. PLoS ONE 9, e112325. doi:10.1371/journal.pone.0112325.

Riedl, V., Valet, M., Wöller, A., Sorg, C., Vogel, D., Sprenger, T., Boecker, H., Wohlschläger, A.M., Tölle, T.R., 2011. Repeated pain induces adaptations of intrinsic brain activity to reflect past and predict future pain. NeuroImage 57, 206–213. doi:10.1016/j.neuroimage.2011.04.011.

Rogers, R., Wise, R.G., Painter, D.J., Longe, S.E., Tracey, I., 2004. An investigation to dissociate the analgesic and anesthetic properties of ketamine using functional magnetic resonance imaging. Anesthesiol. J. Am. Soc. Anesthesiol. 100, 292–301.

Roy, M., Piché, M., Chen, J.-I., Peretz, I., Rainville, P., 2009. Cerebral and spinal modulation of pain by emotions. Proc. Natl. Acad. Sci. 106, 20900–20905. doi:10.1073/pnas.0904706106.

Salomons, T.V., Iannetti, G.D., Liang, M., Wood, J.N., 2016. The "pain matrix" in pain-free individuals. JAMA Neurol. 73, 755–756. doi:10.1001/jamaneurol.2016.0653.

San Emeterio Nateras, O., Yu, F., Muir, E.R., Bazan, C., Franklin, C.G., Li, W., Li, J., Lancaster, J.L., Duong, T.Q., 2015. Intrinsic resting-state functional connectivity in the human spinal cord at 3.0 T. Radiology 279, 262–268. doi:10.1148/radiol.2015150768.

Sandkühler, J., 2009. Models and mechanisms of hyperalgesia and allodynia. Physiol. Rev. 89, 707–758. doi:10.1152/physrev.00025.2008.

Saritas, E.U., Holdsworth, S.J., Bammer, R., 2014. Chapter 2.3 - Susceptibility Artifacts. In: Cohen-Adad, J., Wheeler-Kingshott, C.A.M. (Eds.), Quantitative MRI of the Spinal Cord. Academic Press, San Diego, pp. 91–105. doi:10.1016/B978-0-12-396973-6.00007-1.

Schmidt-Wilcke, T., Ichesco, E., Hampson, J.P., Kairys, A., Peltier, S., Harte, S., Clauw, D.J., Harris, R.E., 2014. Resting state connectivity correlates with drug and placebo response in fibromyalgia patients. NeuroImage Clin. 6, 252–261. doi:10.1016/j.nicl.2014.09.007.

Schweinhardt, P., Kalk, N., Wartolowska, K., Chessell, I., Wordsworth, P., Tracey, I., 2008. Investigation into the neural correlates of emotional augmentation of clinical pain. NeuroImage 40, 759–766. doi:10.1016/j.neuroimage.2007.12.016.

Scott, D.J., Stohler, C.S., Egnatuk, C.M., Wang, H., Koeppe, R.A., Zubieta, J.-K., 2008. Placebo and nocebo effects are defined by opposite opioid and dopaminergic responses. Arch. Gen. Psychiatry 65, 220–231.

Seif, M., Wheeler-Kingshott, C.A.G., Cohen-Adad, J., Flanders, A.E., Freund, P., 2019. Guidelines for the conduct of clinical trials in spinal cord injury: Neuroimaging biomarkers. Spinal Cord 57, 717–728. doi:10.1038/s41393-019-0309-x.

Senapati, A.K., Lagraize, S.C., Huntington, P.J., Wilson, H.D., Fuchs, P.N., Peng, Y.B., 2005. Electrical stimulation of the anterior cingulate cortex reduces responses of rat dorsal horn neurons to mechanical stimuli. J. Neurophysiol. 94, 845–851. doi:10.1152/jn.00040.2005.

Sladky, R., Friston, K.J., Tröstl, J., Cunnington, R., Moser, E., Windischberger, C., 2011. Slice-timing effects and their correction in functional MRI. Neuroimage 58, 588–594. doi:10.1016/j.neuroimage.2011.06.078.

Snoussi, H., Caruyer, E., Cohen-Adad, J., Commowick, O., Combes, B., Bannier, E., Kerbrat, A., Barillot, C., 2019. Geometric evaluation of distortion correction methods in diffusion MRI of the spinal cord. In: Proceedings of the ISBI 2019 - 16th IEEE International Symposium on Biomedical Imaging. IEEE, pp. 1696–1699. doi:10.1109/ISBI.2019.8759196.

Spisak, T., Kincses, B., Schlitt, F., Zunhammer, M., Schmidt-Wilcke, T., Kincses, Z.T., Bingel, U., 2020. Pain-free resting-state functional brain connectivity predicts individual pain sensitivity. Nat. Commun. 11, 1–12. doi:10.1038/s41467-019-13785-z.

Sprenger, C., Eichler, I.-C., Eichler, L., Zöllner, C., Büchel, C., 2018. Altered signaling in the descending pain modulatory system after short-term infusion of the μ-opioid agonist remifentanil. J. Neurosci. doi:10.1523/JNEUROSCI.2496-17.2018, 2496–17.

Sprenger, C., Eippert, F., Finsterbusch, J., Bingel, U., Rose, M., Büchel, C., 2012. Attention modulates spinal cord responses to pain. Curr. Biol. 22, 1019–1022. doi:10.1016/j.cub.2012.04.006.

Sprenger, C., Finsterbusch, J., Büchel, C., 2015. Spinal cord–midbrain functional connectivity is related to perceived pain intensity: a combined spino-cortical fMRI study. J. Neurosci. 35, 4248–4257. doi:10.1523/JNEUROSCI.4897-14.2015.

Sprenger, T., Valet, M., Woltmann, R., Zimmer, C., Freynhagen, R., Kochs, E.F., Tölle, T.R., Wagner, K.J., 2006. Imaging pain modulation by subanesthetic S-(+)-ketamine. Anesth. Analg. 103, 729–737. doi:10.1213/01.ane.0000231635.14872.40.

Stockmann, J.P., Witzel, T., Keil, B., Polimeni, J.R., Mareyam, A., LaPierre, C., Setsompop, K., Wald, L.L., 2016. A 32-channel combined RF and B0 shim array for 3T brain imaging. Magn. Reson. Med. 75, 441–451. doi:10.1002/mrm.25587.

Stroman, P.W., Bosma, R.L., Cotoi, A.I., Leung, R.H., Kornelsen, J., Lawrence-Dewar, J.M., Pukall, C.F., Staud, R., 2016a. Continuous descending modulation of the spinal cord revealed by functional MRI. PLoS ONE 11, e0167317. doi:10.1371/journal.pone.0167317.

Stroman, P.W., Bosma, R.L., Tsyben, A., 2012. Somatotopic arrangement of thermal sensory regions in the healthy human spinal cord determined by means of spinal cord functional MRI. Magn. Reson. Med. 68, 923–931. doi:10.1002/mrm.23292.

Stroman, P.W., Coe, B.C., Munoz, D.P., 2011. Influence of attention focus on neural activity in the human spinal cord during thermal sensory stimulation. Magn. Reson. Imaging 29, 9–18. doi:10.1016/j.mri.2010.07.012.

Stroman, P.W., Figley, C.R., Cahill, C.M., 2008. Spatial normalization, bulk motion correction and coregistration for functional magnetic resonance imaging of the human cervical spinal cord and brainstem. Magn. Reson. Imaging 26, 809–814. doi:10.1016/j.mri.2008.01.038.

Stroman, P.W., Ioachim, G., Powers, J.M., Staud, R., Pukall, C., 2018. Pain processing in the human brainstem and spinal cord before, during, and after the application of noxious heat stimuli. PAIN 159, 2012. doi:10.1097/j.pain.0000000000001302.

Stroman, P.W., Khan, H.S., Bosma, R.L., Cotoi, A.I., Leung, R., Cadotte, D.W., Fehlings, Michael.G., 2016b. Changes in pain processing in the spinal cord and brainstem after spinal cord injury characterized by functional magnetic resonance imaging. J. Neurotrauma 33, 1450–1460. doi:10.1089/neu.2015.4257.

Stroman, P.W., Wheeler-Kingshott, C., Bacon, M., Schwab, J.M., Bosma, R., Brooks, J., Cadotte, D., Carlstedt, T., Ciccarelli, O., Cohen-Adad, J., Curt, A., Evangelou, N., Fehlings, M.G., Filippi, M., Kelley, B.J., Kollias, S., Mackay, A., Porro, C.A., Smith, S., Strittmatter, S.M., Summers, P., Tracey, I., 2014. The current state-of-the-art of spinal cord imaging: Methods. NeuroImage 84, 1070–1081. doi:10.1016/j.neuroimage.2013.04.124.

Summers, P.E., Brooks, J.C.W., Cohen-Adad, J., 2014. Chapter 4.1 - Spinal Cord fMRI. In: Cohen-Adad, J., Wheeler-Kingshott, C.A.M. (Eds.), Quantitative MRI of the Spinal Cord. Academic Press, San Diego, pp. 221–239. doi:10.1016/B978-0-12-396973-6.00015-0.

Summers, P.E., Ferraro, D., Duzzi, D., Lui, F., Iannetti, G.D., Porro, C.A., 2010. A quantitative comparison of BOLD fMRI responses to noxious and innocuous stimuli in the human spinal cord. NeuroImage 50, 1408–1415. doi:10.1016/j.neuroimage.2010.01.043.

Tabelow, K., Balteau, E., Ashburner, J., Callaghan, M.F., Draganski, B., Helms, G., Kherif, F., Leutritz, T., Lutti, A., Phillips, C., Reimer, E., Ruthotto, L., Seif, M., Weiskopf, N., Ziegler, G., Mohammadi, S., 2019. hMRI – A toolbox for quantitative MRI in neuroscience and clinical research. NeuroImage 194, 191–210. doi:10.1016/j.neuroimage.2019.01.029.

Tagliazucchi, E., Balenzuela, P., Fraiman, D., Chialvo, D.R., 2010. Brain resting state is disrupted in chronic back pain patients. Neurosci. Lett. 485, 26–31. doi:10.1016/j.neulet.2010.08.053.

Taso, M., Le Troter, A., Sdika, M., Ranjeva, J.-P., Guye, M., Bernard, M., Callot, V., 2014. Construction of an in vivo human spinal cord atlas based on high-resolution MR images at cervical and thoracic levels: Preliminary results. Magn. Reson. Mater. Phys. Biol. Med. 27, 257–267. doi:10.1007/s10334-013-0403-6.

Tinnermann, A., Geuter, S., Sprenger, C., Finsterbusch, J., Büchel, C., 2017. Interactions between brain and spinal cord mediate value effects in nocebo hyperalgesia. Science 358, 105–108. doi:10.1126/science.aan1221.

Topfer, R., Foias, A., Stikov, N., Cohen-Adad, J., 2018. Real-time correction of respiration-induced distortions in the human spinal cord using a 24-channel shim array. Magn. Reson. Med. 80, 935–946. doi:10.1002/mrm.27089.

Topfer, R., Starewicz, P., Lo, K.-M., Metzemaekers, K., Jette, D., Hetherington, H.P., Stikov, N., Cohen-Adad, J., 2016. A 24-channel shim array for the human spinal cord: design, evaluation, and application. Magn. Reson. Med. 76, 1604–1611. doi:10.1002/mrm.26354.

Tracey, I., Mantyh, P.W., 2007. The cerebral signature for pain perception and its modulation. Neuron 55, 377–391. doi:10.1016/j.neuron.2007.07.012.

Tracey, I., Woolf, C.J., Andrews, N.A., 2019. Composite pain biomarker signatures for objective assessment and effective treatment. Neuron 101, 783–800. doi:10.1016/j.neuron.2019.02.019.

Upadhyay, J., Anderson, J., Schwarz, A.J., Coimbra, A., Baumgartner, R., Pendse, G., George, E., Nutile, L., Wallin, D., Bishop, J., Neni, S., Maier, G., Iyengar, S., Evelhoch, J.L., Bleakman, D., Hargreaves, R., Becerra, L., Borsook, D., 2011. Imaging drugs with and without clinical analgesic efficacy. Neuropsychopharmacology 36, 2659–2673. doi:10.1038/npp.2011.156.

Vahdat, S., Khatibi, A., Lungu, O., Finsterbusch, J., Büchel, C., Cohen-Adad, J., Marchand-Pauvert, V., Doyon, J., 2020. Resting-state brain and spinal cord networks in humans are functionally integrated. PLOS Biol 18, e3000789. doi:10.1371/journal.pbio.3000789.

Vahdat, S., Lungu, O., Cohen-Adad, J., Marchand-Pauvert, V., Benali, H., Doyon, J., 2015. Simultaneous brain-cervical cord fMRI reveals intrinsic spinal cord plasticity during motor sequence learning. PLoS Biol 13, e1002186. doi:10.1371/journal.pbio.1002186.

Valet, M., Sprenger, T., Boecker, H., Willoch, F., Rummeny, E., Conrad, B., Erhard, P., Tolle, T.R., 2004. Distraction modulates connectivity of the cingulo-frontal cor-

tex and the midbrain during pain – An fMRI analysis. PAIN 109, 399–408. doi:10.1016/j.pain.2004.02.033.

Valsasina, P., Horsfield, M.A., Rocca, M.A., Absinta, M., Comi, G., Filippi, M., 2012. Spatial normalization and regional assessment of cord atrophy: voxel-based analysis of cervical cord 3D T1-weighted images. Am. J. Neuroradiol. 33, 2195–2200. doi:10.3174/ajnr.A3139.

Vannesjo, S.J., Miller, K.L., Clare, S., Tracey, I., 2017. Spatiotemporal characterization of breathing-induced B0 field fluctuations in the cervical spinal cord at 7T. NeuroImage 167, 191–202. doi:10.1016/j.neuroimage.2017.11.031.

Verma, T., Cohen-Adad, J., 2014. Effect of respiration on the B0 field in the human spinal cord at 3T. Magn. Reson. Med. 72, 1629–1636. doi:10.1002/mrm.25075.

Verne, G.N., Himes, N.C., Robinson, M.E., Gopinath, K.S., Briggs, R.W., Crosson, B., Price, D.D., 2003. Central representation of visceral and cutaneous hypersensitivity in the irritable bowel syndrome. PAIN 103, 99–110. doi:10.1016/S0304-3959(02)00416-5.

Voss, H.U., Watts, R., Uluğ, A.M., Ballon, D., 2006. Fiber tracking in the cervical spine and inferior brain regions with reversed gradient diffusion tensor imaging. Magn. Reson. Imaging 24, 231–239. doi:10.1016/j.mri.2005.12.007.

Waber, B.S.R.L., 2008. Commercial features of placebo and therapeutic efficacy. J. Am. Med. Assoc. 299, 1016–1017. doi:10.1001/jama.299.9.1016.

Wager, T.D., Atlas, L.Y., 2015. The neuroscience of placebo effects: connecting context, learning and health. Nat. Rev. Neurosci. 16, 403–418. doi:10.1038/nrn3976.

Wager, T.D., Atlas, L.Y., Botvinick, M.M., Chang, L.J., Coghill, R.C., Davis, K.D., Iannetti, G.D., Poldrack, R.A., Shackman, A.J., Yarkoni, T., 2016. Pain in the ACC? Proc. Natl. Acad. Sci. 113, E2474–E2475. doi:10.1073/pnas.1600282113.

Wager, T.D., Atlas, L.Y., Lindquist, M.A., Roy, M., Woo, C.-W., Kross, E., 2013. An fMRI-based neurologic signature of physical pain. N. Engl. J. Med. 368, 1388–1397. doi:10.1056/NEJMoa1204471.

Wager, T.D., Rilling, J.K., Smith, E.E., Sokolik, A., Casey, K.L., Davidson, R.J., Kosslyn, S.M., Rose, R.M., Cohen, J.D., 2004. Placebo-induced changes in fMRI in the anticipation and experience of pain. Science 303, 1162–1167. doi:10.1126/science.1093065.

Wager, T.D., Scott, D.J., Zubieta, J.-K., 2007. Placebo effects on human μ-opioid activity during pain. Proc. Natl. Acad. Sci. 104, 11056–11061. doi:10.1073/pnas.0702413104.

Wanigasekera, V., Lee, M.C., Rogers, R., Kong, Y., Leknes, S., Andersson, J., Tracey, I., 2012. Baseline reward circuitry activity and trait reward responsiveness predict expression of opioid analgesia in healthy subjects. Proc. Natl. Acad. Sci. 109, 17705–17710. doi:10.1073/pnas.1120201109.

Wanigasekera, V., Wartolowska, K., Huggins, J.P., Duff, E.P., Vennart, W., Whitlock, M., Massat, N., Pauer, L., Rogers, P., Hoggart, B., Tracey, I., 2018. Disambiguating pharmacological mechanisms from placebo in neuropathic pain using functional neuroimaging. Br. J. Anaesth. 120, 299–307. doi:10.1016/j.bja.2017.11.064.

Weber, K.A., Chen, Y., Wang, X., Kahnt, T., Parrish, T.B., 2016a. Lateralization of cervical spinal cord activity during an isometric upper extremity motor task with functional magnetic resonance imaging. NeuroImage 125, 233–243. doi:10.1016/j.neuroimage.2015.10.014.

Weber, K.A., Chen, Y., Wang, X., Kahnt, T., Parrish, T.B., 2016b. Functional magnetic resonance imaging of the cervical spinal cord during thermal stimulation across consecutive runs. NeuroImage 143, 267–279. doi:10.1016/j.neuroimage.2016.09.015.

Weber, K.A., Sentis, A.I., Bernadel-Huey, O.N., Chen, Y., Wang, X., Parrish, T.B., Mackey, S., 2018. Thermal stimulation alters cervical spinal cord functional connectivity in humans. Neuroscience 369, 40–50. doi:10.1016/j.neuroscience.2017.10.035.

Wei, P., Li, J., Gao, F., Ye, D., Zhong, Q., Liu, S., 2009. Resting state networks in human cervical spinal cord observed with fMRI. Eur. J. Appl. Physiol. 108, 265. doi:10.1007/s00421-009-1205-4.

Williams, A.E., Heitkemper, M., Self, M.M., Czyzewski, D.I., Shulman, R.J., 2013. Endogenous inhibition of somatic pain is impaired in girls with irritable bowel syndrome compared with healthy girls. J. Pain 14, 921–930. doi:10.1016/j.jpain.2013.03.003.

Wise, R.G., Rogers, R., Painter, D., Bantick, S., Ploghaus, A., Williams, P., Rapeport, G., Tracey, I., 2002. Combining fMRI with a pharmacokinetic model to determine which brain areas activated by painful stimulation are specifically modulated by remifentanil. NeuroImage 16, 999–1014. doi:10.1006/nimg.2002.1146.

Wise, R.G., Tracey, I., 2006. The role of fMRI in drug discovery. J. Magn. Reson. Imaging 23, 862–876. doi:10.1002/jmri.20584.

Wise, R.G., Williams, P., Tracey, I., 2004. Using fMRI to quantify the time dependence of remifentanil analgesia in the human brain. Neuropsychopharmacology 29, 626. doi:10.1038/sj.npp.1300364.

Woolf, C.J., 2011. Central sensitization: Implications for the diagnosis and treatment of pain. PAIN 152, S2–S15. doi:10.1016/j.pain.2010.09.030.

Xu, J., Shimony, J.S., Klawiter, E.C., Snyder, A.Z., Trinkaus, K., Naismith, R.T., Benzinger, T.L.S., Cross, A.H., Song, S.-K., 2013. Improved in vivo diffusion tensor imaging of human cervical spinal cord. NeuroImage 67, 64–76. doi:10.1016/j.neuroimage.2012.11.014.

Xue, T., Yuan, K., Zhao, Ling, Yu, D., Zhao, Limei, Dong, T., Cheng, P., von Deneen, K.M., Qin, W., Tian, J., 2012. Intrinsic brain network abnormalities in migraines without aura revealed in resting-state fMRI. PLoS ONE 7, e52927. doi:10.1371/journal.pone.0052927.

Yang, P.-F., Wang, F., Chen, L.M., 2015. Differential fMRI activation patterns to noxious heat and tactile stimuli in the primate spinal cord. J. Neurosci. 35, 10493–10502. doi:10.1523/JNEUROSCI.0583-15.2015.

Zaki, J., Ochsner, K.N., Hanelin, J., Wager, T.D., Mackey, S.C., 2007. Different circuits for different pain: patterns of functional connectivity reveal distinct networks for processing pain in self and others. Soc. Neurosci. 2, 276–291. doi:10.1080/17470910701401973.

Zheng, W., Woo, C.-W., Yao, Z., Goldstein, P., Atlas, L.Y., Roy, M., Schmidt, L., Krishnan, A., Jepma, M., Hu, B., Wager, T.D., 2019. Pain-evoked reorganization in functional brain networks. Cereb. Cortex bhz276. 10.1093/cercor/bhz276.